51



Integument and its Derivatives in Vertebrates

Comparative Anatomy, its Meaning and Purpose of Study

Study of the structure of animals is termed *anatomy*, whereas a comparative study of structure of different animal groups, or animals, is known as *comparative anatomy*. In fact the study of comparative anatomy is more purposeful and dynamic than mere study of the location and structure of different organ systems in different animals. It also determines the phylogenetic origin and modification of their various homologous structures. In a sense, it is the history of the struggle of animals, striving for compatibility with an ever changing environment in the past. Despite their differences, all vertebrates, past as well as present, are built according to the same basic architectural plan. Thus, comparative study of various homologous vertebrate structures offers special evidence in support of the doctrine of organic evolution with the premise that species have been changing.

Integument or Skin

Definition. The term *integument* is applied to the outermost protective covering of the animal body, the *skin*, and its various *derivatives*. Skin also includes the conjunctiva of eyeballs and external surface of eardrums. It is directly continuous with the mucous epithelial lining of mouth, rectum, nostrils, eyelids and urinogenital ducts.

[I] Functions of integument

The integument or skin of vertebrates is truly a 'jack-of-all-trades' since it performs several important functions —

1. Protection. The integument or skin separates the animal from its external environment and helps to maintain a constant internal environment. It has several protective devices—

(1) It protects the body against a variety of mechanical and chemical injuries which may result from pressure, friction, blows, harmful gases and fluids.

(2) Protective derivatives such as scales, bony plates, fat, feathers, hairs, etc. reduce the force of injury, prevent excessive loss of body moisture and do not allow entry of harmful bacteria and fungi, and other foreign bodies.

(3) Pelage (fur), plumage (feathers), bristles or spines, claws, nails, hoofs, antlers, horns, etc. serve for offence and defence.

(4) Protective colouration or camouflage serves to escape detection by enemies.

(5) Skin pigments also protect against solar radiation.

2. Locomotion. Dermal fin rays in the fins of fishes and skin webs in the feet of frogs, turtles, aquatic birds, etc., help in swimming in water. Adhesive pads (Amphibia) and claws (amniotes) on digits assist in climbing. Feathers on wings and short tail of birds and cutaneous patagia or wings of bats and flying lizards and squirrels help in flying.

3. Dermal endoskeleton. Skin contributes to bony dermal armour such as in extinct ostracoderms and placoderms and living sturgeons, crocodiles and turtles. Dermal endoskeleton in head, shields the brain and sense organs. Elsewhere it prevents compression of soft internal organs and also forms parts of teeth.

4. Secretion. Skin glands secrete substances having several uses. (i) Mucous glands in aquatic forms (e.g., fish, frog) keep the skin moist and slippery. (ii) Poisonous, bitter or offensive secretions ward off potential enemies. (iii) Uropygial glands in birds secrete oil for preening feathers. (iv) Oil from sebaceous glands of mammals lubricates the skin and hairs. Moreover, *sebum* contains *fatty acids* and *lactic acids* in it which bring down the pH of skin to 3-A and creates a hostile environment for growth, multiplication and survival of microbes. (v) Mammary glands manufacture milk for nourishment of the young. (vi) Odours of scent glands attract the opposite sex. (vii) Tears from lacrymal glands wash the conjunctiva of mammalian eye ball. (viii) Glands of auditory meatus secrete an earwax, the cerumen, to grease eardrums and to entrap insects that enter the canal.

5. Food storage. Thick fatty layer of blubber under skin of seals and whales serves as insulation as well as reserve food. Animals also accumulate subcutaneous fat prior to hibernation and migration.

6. Temperature control. In warm-blooded animals, fur, feathers and scales insulate and conserve body heat in cold climate. Sweat glands of mammals provide cooling by evaporation in summer. For elimination of heat, integumentary blood vessels dilate so that skin becomes a radiator. For conservation of heat, the vessels constrict. These devices help in homoiothermy or in the maintenance of constant body temperature.

7. Excretion. Excess of water, salts and urea are also eliminated in sweat. Gills of marine fishes contain chloride-secreting cells. Shedding of skin during ecdysis also gets rid off of some metabolic wastes.

8. Sensation. Cutaneous nerve endings and other sense organs are stimulated by touch, pain, changes in pressure and moisture, extremes of heat and cold and chemicals, etc. In their absence, these animals may starve or destroyed by an enemy.

9. Sexual selection. Brilliantly coloured skins, antlers of male deer, long tail coverts of peacock, etc. lead to sexual dimorphism and also serve to attract the females for mating.

10. Miscellaneous. Skin has many other functions not cited above. (i) Vitamin D is synthesized in mammalian skin from sebum of sebaceous glands in ultra-violet light. (ii) Brood pouches under the skin of some fishes and amphibians protect unhatched eggs. (iii) Nasal glands of tetrapods keep nostrils free of water and dirt. (iv) Amphibians and other aquatic animals carry on considerable respiration through their richly vascular skin. (v) Skin shows selective absorption of oils, ointments, iodine, beneficial sun-rays, etc. (vi) Special types of enzymes are produced by larvae of some fishes and frogs.

[II] Structure of integument in general

The skin of all vertebrates is built according with the same basic plan. It is multicellular and differs from that of the invertebrates in having two layers— (i) an outer *epidermis* developed from ectoderm, and (ii) an inner *dermis* derived from the mesoderm. The related abundance of the two layers differs according to the environment.

1. Epidermis. Epidermis is a stratified epithelium and normally quite thin in comparison to dermis. It is further distinguished into two regions— (i) The outermost region of many layers of dead usually flattened (squamous) cells forms a horny, resistant covering or *stratum corneum* on the skin surface. Its cells accumulate a horny protein, called *keratin*, gradually die and eventually wear off in the form of scurf or dandruff. Since keratin is tough and insoluble in water, the keratinized stratum corneum provides protection against mechanical injuries, fungal and bacterial attacks and loss of body moisture. (ii) The innermost or basal region of epidermis includes a single row of living columnar cells, the *Malpighian layer* or *stratum germinativum*, which is separated from the underlying dermis by a basement membrane. Its cells actively divide and continually replace the worn out cells of the cornified layer.

Epidermis is thin in aquatic vertebrates and rich in mucous glands. It is thicker in land vertebrates and structures such as scales, feathers, hairs, nails, claws, horns and enamel of teeth are derived from its Malpighian layer.

2. Dermis. Dermis or *corium*, which is the inner layer of skin, is comparatively thicker than epidermis. It is composed of fibrous connective tissue and contains many blood capillaries, lymph vessels, muscle fibres, nerve fibres, sense organs and elastic fibres which bring the skin back to its normal shape. Pigment cells or *melanocytes* are mostly located in dermis, although sometimes pigment granules are also found in epidermis. Fat may accumulate as reserve food in special cells, called *adipocytes*, in deeper parts of dermis and in the subcutaneous tissue.

Derivatives of Integument

The skin itself is relatively simple but its derivatives are numerous and complex. Depending on the layer of skin from which they are derived, these structures fall under two broad categories : *epidermal* and *dermal*.

1. Epidermal derivatives. These are formed by the epidermis and comprise : (i) *epidermal glands* and (ii) *hard horny structures* including *epidermal scales, scutes, beaks, horns, claws, nails* and *hoofs, feathers* and *hairs*, etc. All the hard horny structures together form the *exoskeleton* of an animal.

2. Dermal derivatives. These arise from dermis and comprise *bony* or *dermal scales, plates* or *scutes, fin-rays* and *antlers*, etc.

[I] Epidermal glands

Integumental or epidermal glands are formed by the Malpighian layer of epidermis. They arise in epidermis but often invade the dermis. They may be unicellular or multicellular, tubular or alveolar in shape, and simple, compound or branched. They are lined by cuboidal cells or columnar epithelium. They are usually named after their nature or function. The 9 major types described below are : mucous, poison, luminescent, femoral, uropygial, sweat, sebaceous, scent and mammary.

1. Mucous glands. They secrete *mucin* which forms slimy or sticky mucous on coming in contact with water. Mucous keeps the skin moist and slippery and protects against harmful bacteria and fungi. They are abundant in amphibian skin. They may be unicellular or multicellular eg., granular cells, beaker cells of amphioxus, cyclostomes, fishes etc.

2. Poison glands. Many fishes and amphibians have poison glands. These are modified multicellular cutaneous glands, larger but fewer than mucous glands. The parotid glands behind the head of toads are aggregations of poison glands. Secretion of poison glands may be bitter, irritating and even dangerous to the predators. Poison glands of amphibians are granular glands collected into masses called, *Parotid glands*. The poison secreted by it is *alkaloid* and similar in action like digitalis.

3. Luminescent glands or photophores. In deep sea luminous teleost fishes, certain multicellular epidermal glands serve as light-emitting organs, known as *photophores*. In one type of photophore, the superficial layer of mucous cells forms a magnifying lens, lower or basal part consists of luminous cells surrounded below by reflecting pigment cells. The reflector is made of *guanine* crystals. Light emitted is not intense, may be of many hues, and serves to attract preys. They can be flashed on and off, by *sympathetic nerves*. Injections of *adrenaline* produce flashes in some species like *Spinax*.

4. Femoral glands. These are found in male lizards (e.g. *Uromastix*) on the ventral surface of each thigh, in a single row 12-18 *femoral pores* from knee to cloacal aperture. Their sticky secretion hardens in air to form temporary tiny spines that serve to hold the female during copulation.

5. Uropygial gland. It is one of the few integumentary glands found in birds, forming a prominent swelling just above the tail or uropygium. It is branched and alveolar and exudes an oily secretion used for lubricating beak, preening feathers and attracting the opposite sex during breeding season due to odoriferous nature. The oil secreted by it contains *pomatum* which is picked up by beak and used for preening and water proofing.

6. Sweat glands. Sweat glands or sudoriferous glands (*sudor* = sweat) are abundant in the skin of most mammals. They are slender coiled tubes embedded deep in the dermis, with their long ducts opening on skin surface. A little urea and some salts are eliminated dissolved in water in the sweat produced by these glands. Evaporation of watery perspiration also helps to cool and regulate body temperature in hot environments.

Sweat glands are absent in spiny scaly anteaters and marine forms such as Sirenia and Cetacea. In many mammals their distribution is restricted. They may occur only on the soles of feet (cats and mice), lips (rabbits), muzzle and skin between toes (ruminants), sides of head (bats), ears (hippopotamus), etc. Male giant Kangaroo (*Macropus rufus*) and hippopotamus secrete red-coloured sweat. *Ciliary glands* in eyelashes and along margins of eyelids are modified sweat glands.

7. Sebaceous glands. These are branched alveolar glands opening into hair follicles of mammals. They may open directly onto skin surface such as around the genital organs, tip of nose or edges of lips. Their oily secretion, called *sebum* (=grease), keeps the skin and hairs soft, greasy, water-proof and glistening.

Sebaceous glands absent in pangolins and marine mammals (Sirenia, Cetacea) which are practically devoid of hairs. *Ceruminous glands* of external ear canals are modified sebaceous glands. Their waxy or greasy secretion, called *cerumen*, helps trap insects or dust particles. Similarly, *meibomian glands* of eyelids, which spread their oily secretion over the exposed surface of eyeball, are modified sebaceous glands.

8. Scent glands. These are modifications either of sebaceous or sudoriferous glands of mammals. Their odorous secretions serve to repel foes or attract members of opposite sex. Scent glands may occur between toes on feet (goat, rhino, horse), near eyes on head (deer family), navel on abdomen (musk deer), mid-dorsally on back (Kangaroo rats *Dipodomys*), around anus (skunks, many carnivores and rodents), etc.

In a zoo, many foul odours may not be due to unhygienic conditions but caused by the scent glands of mammals in the pens and cages.

9. Mammary glands. Characteristic of mammals, these are compound tubular glands that produce milk during lactation period for feeding the young ones. Usually they occur only on females, but are also present on males in monotremes, primates and some others. In monotremes, the mammary glands lack nipples or teats and resemble modified sweat glands. In other mammals, they possess nipples and are modifies sebaceous glands.

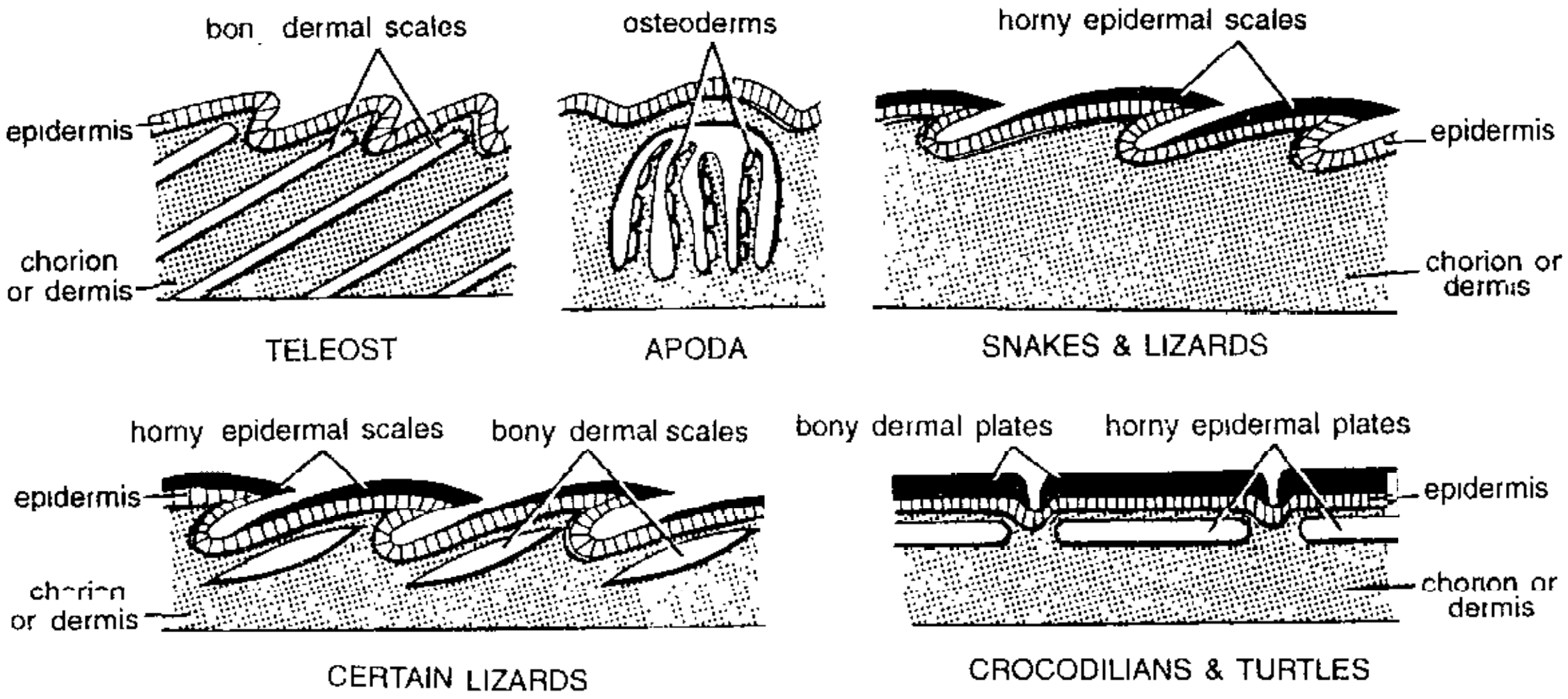

Fig. 1 Diagrammatic V.S through skins of various vertebrates showing relationship of various types of scales.

Distribution and number of mammary glands and nipples vary with the species. A *nipple* is a raised conical or elongated elevation of body surface bearing the opening of milk gland. In *true teats* (man, apes), ducts of mammary glands open separately on the nipple. In *false teats* (ungulates), all ducts empty into one cistern from which a single tube leads to the tip of the nipple.

[II] Epidermal scales and scutes

All the hard horny structures develop by the accumulation of a scleroprotein, known as *keratin*, in the cells of epidermis. Such cells are said to be keratinized or cornified, and they become dead. All stratum corneum cells are cornified and form hard horny exoskeletal structures like scales, beaks, horns, claws, nails, hoofs, feathers, hairs, etc. in different vertebrates.

Reptiles have a continuous outer covering of horny epidermal scales that prevents water loss through skin surface. In lizards, scales are thin, small, overlapping and periodically moulted in small pieces. In snakes also the scales are overlapping, enlarged on head, called *shields*, and on ventral surface, called *scutes*, which aid in locomotion. In most snakes and some lizards, the stratum corneum of entire body is periodically shed in one piece at the time of ecdysis or moulting. Crocodilians and turtles have large, thick, rectangular *scutes*, not overlapping but touching each other, and supported beneath by dermal bones. Scutes of crocodilians are sloughed or shed in patches at intervals. The toothless horny *beak* of turtles, the *rattle* at the end of the tail of rattle snakes and *horns* of the horned toad (a lizard) are other modifications of stratum corneum in reptiles.

In birds, small epidermal scales are present on the lower leg, foot and base of beak. The sheath of beak (*rhamphotheca*) is also a modification of stratum corneum.

Reptile-like epidermal scales occur in some mammals also, such as on the feet and tails of rats and beavers, etc. The *large scales* on the body of a scaly anteater undergo ecdysis individually. In armadillos, large body scales become fused into *plates* and *bands*. They are supported beneath by dermal bony scales and do not moult.

[III] Dermal scales and scutes

Bony structures develop within the dermis and are mesodermal in origin (Fig. 1). Thick bony scales and plates formed a heavy armour in the extinct ostracoderms. But they have been retained in reduced form in most living fishes, reptiles and others. In contrast to the horny epidermal scales, the bony dermal scales are not shed but increase in size during life by the addition of new bone.

1. Dermal scales of fishes. As mentioned above bony or dermal scales develop in the dermis. In fishes, the overlying epidermis wears off so that the scales become exposed forming the *exoskeleton.* Five types of dermal scales are known, depending on their structure, in fishes. (i) *Cosmoid* scales occurred in extinct lobe-finned fishes (Crossopterygii). (ii) *Placoid* scales are characteristic of elasmobranchs (Chondrichthyes). (iii) *Ganoid* scales are present in ganoid fishes (chondrosteans and holosteans). (iv) *Cycloid* and (v) *Ctenoid* scales are characteristic of modern teleosts. For more details, readers may refer to Chapter 18 and Figure 5.

2. Dermal scales and scutes of tetrapods. Dermal scales or bony plates measuring 1 to 2 mm, called *osteoderms*, are found embedded in the pockets of dermis below epidermis, in some caecilians or Apoda (Amphibia). They also occur in the back of some tropical toads.

In addition to epidermal scales and scutes, reptiles also retain traces of bony dermal armour of their ancestors. A few lizards exhibit small *dermal scales*. Crocodiles and alligators have many oval *bony plates* embedded in the dermis of their back and neck. In turtles, below horny epidermal scutes, are present large *bony plates* or *osteoderms*, forming a box-like continuous rigid dermal skeleton around trunk and including a dorsally arched *carapace* and a ventral flattened *plastron*.

Amongst mammals, bony plates or osteoderms occur in armadillos and whales.

3. Dermal fin rays. Supporting the fins of fishes are long, flexible fin rays embedded in dermis. In Chondrichthyes, they are horny, hair-like, made of fibrous connective tissue and called *ceratotrichia* (*cerato* = horn + *tricho* =hair). In Osteichthyes, they are branched, made of a series of segments or scales, and called *lepidotrichia* (*lepido* = scale). Unsegmented, sharp and spine-like fin rays are termed *actinotrichia*.

[IV] Digital cornifications

All digital cornifications, that is, claws, nails and hoofs, are built on the same plan (Fig. 2). They are modification of stratum corneum at the tips of digits and grow parallel to the skin.

1. Claws. Claws of reptiles, birds and mammals are identical in structure. A claw is made by a hard, pointed, narrow, curved, horny dorsal plate, called *unguis*, and a less hard ventral plate, called *subunguis*, both enclosing the tip of the digit covering the last tapering phalanx.

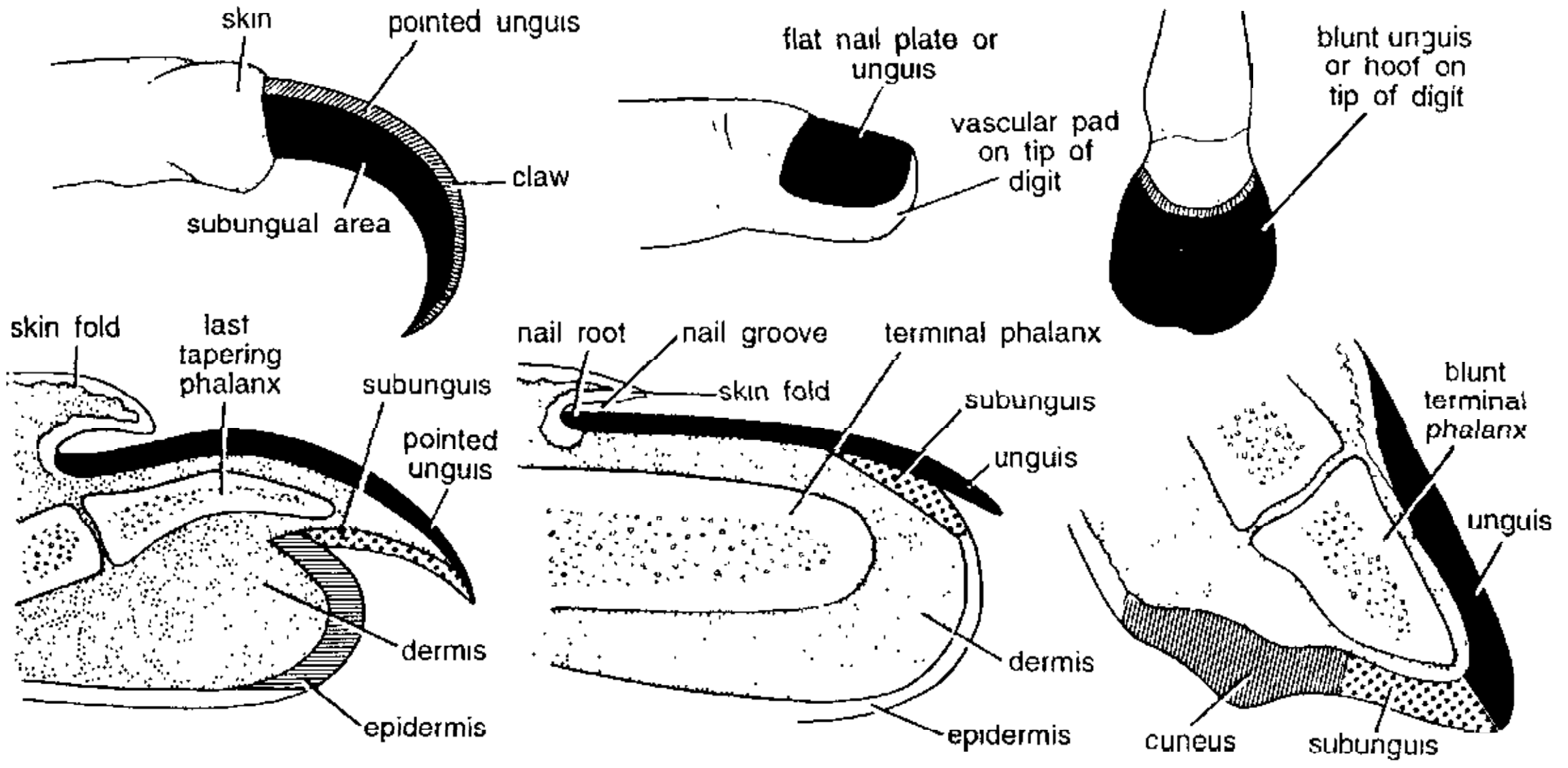

CLAW NAIL HOOF

Fig. 2. Relation between claw (eagle), nail (human) and hoof (horse). Digital tips shown complete above and in sagittal sections below

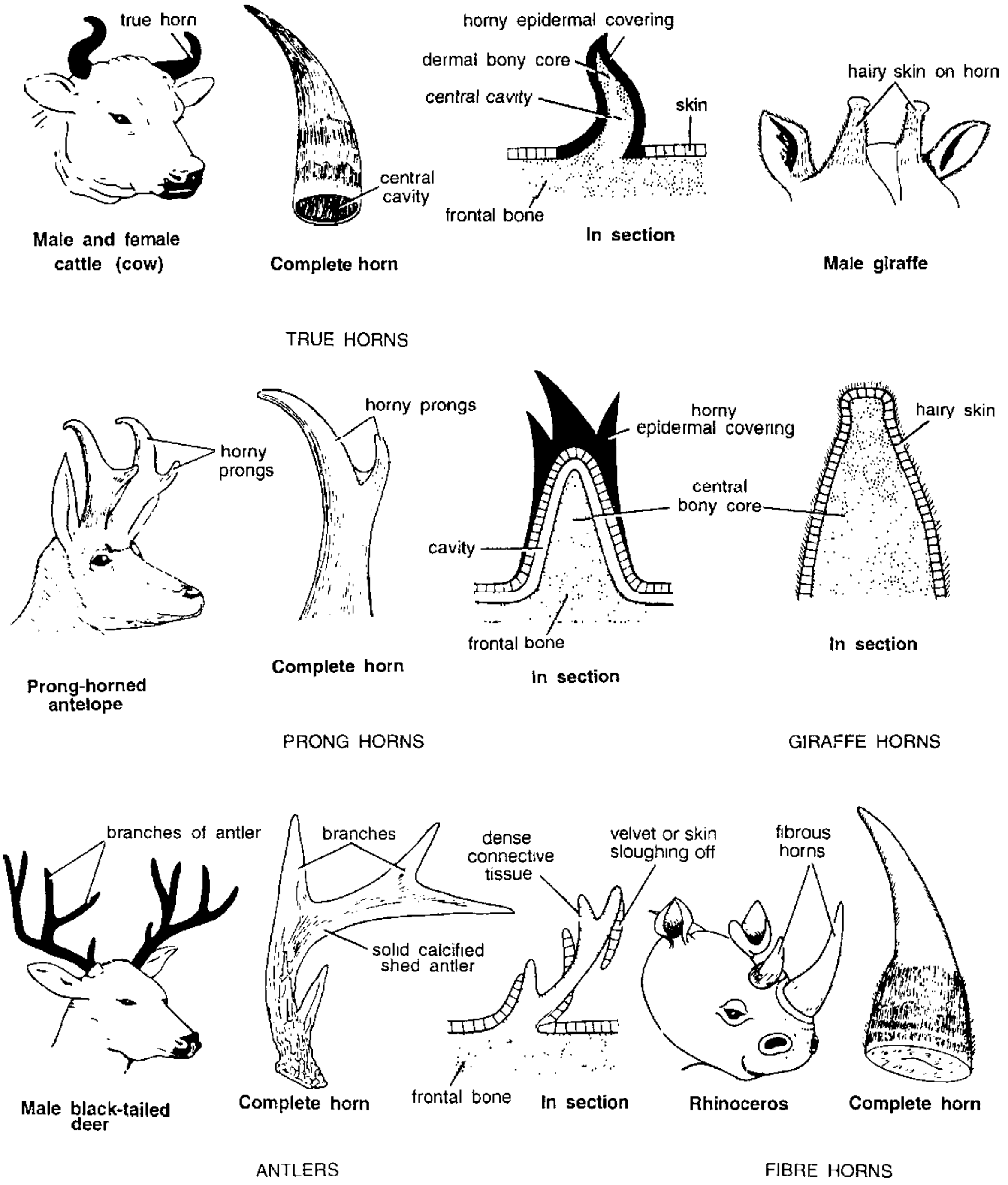

Fig 3. Types of mammalian horns and antlers.

2. Nails. Claws are modified into nails which are characteristic of Primates (mammals). Dorsal plate or unquis is broad and flat, while subunguis is softer and much reduced. The tip of the digit forms a greatly sensitive and highly vascular *pad* over which the epidermis invaginates to form a *nail groove* containing the nail root.

3. Hoofs. Hoofs are characteristic of ungulates (hoofed mammals). The horny unguis is neither pointed nor flat, but U- or V-shaped. Subunguis is also U-shaped, greatly thickened and touching ground. The horse's shoe can be nailed into it. Subunguis surrounds a softer horny substance, the *cuneus*. The tip of digit forms a pad and contains a blunt phalanx.

Other modifications of stratum corneum include the *whalebone plates* of toothless whales, and the *horny coverings* of horns of sheep and cattle and prong horns of antelopes.

[V] Horns

Horns are found in hoofed mammals (Artiodactyla and Perissodactyla) only (Fig. 3). They are present on their head and form organs of offense and defense. At least 5 types of horns are recognized, but all are not true horns, that is, product of stratum corneum.

1. True horns. True or hollow horns usually occur in both the sexes in goats, sheep, cattle and others. They are unbranched, cylindrical and tapering. They are permanent structures that continue to grow throughout life and are never shed. The true horn is made of a hollow dermal bony core arising from frontal bone of skull, and covered by an epidermal horny hollow cap.

2. Prong horns. The horns of prong-horned antelope (*Antilocapra*) are also true horns. It is formed by a small central permanent bony core arising from frontal bone and covered by a thin hollow and horny epidermal horn. But the horny sheath of a prong horn bears 1 to 3 branches or prongs, and it is shed every year. The permanent bony core becomes the base around which a new horn is developed the following year.

3. Antlers. Antlers are characteristic of deer family. They are found only on males but on both the sexes in reindeer and caribou. Antlers are annual growths and not true horns. An antler is a branching solid outgrowth of dense connective tissue connected basally to the frontal bone of skull. Deposition of calcium salts makes the antler hard. During growth, it is covered on the surface with typical hairy and vascular skin, or 'velvet'. When growth is complete, the velvet wears off, exposing the naked, branched antler. After the breeding season is over, the antlers are also shed and new antlers develop the following year.

4. Giraffe horns. Horns of giraffes are stunted, unbranched and permanent antlers present in both sexes. Each consists of a short bony dermal core, projecting from frontal bone and remains covered with simple unmodified skin or velvet which is never shed.

5. Hair horns. Hair horns or fibre horns are found in rhinoceros of both sexes. Perched upon a roughened area of nasal bones. Indian rhino has a single horn, while the African species has two, one behind the other. These horns are entirely made of thick hairy and keratinized epidermal fibres fused together. These are permanent structures and if broken they again grow out. Rhinoceroses are still slaughtered illegally because these horns are in great demand in Oriental countries as a love charm.

[VI] Feathers

Birds are covered by feathers which are not found in any other group of animals. They are dry, non-living and cornified products of stratum corneum of epidermis. These unique structures are light in weight, but strong, elastic and water-proof. They show different colours due to presence of pigments of various shades and structural arrangement. They mainly streamline and protect the body, conserve body heat and make broad surfaces of wings and tail used for flight. The mode of development of feathers is like that of scales. Feathers are moulted and replaced seasonally.

Generally, three types of feathers are recognized : countour, down (plumules) and filoplumes (hair-like). For a detailed treatment of the structure, development, kinds and uses of feathers, readers may refer to Chapter 27.

[VII] Hairs

Hairs are characteristic of mammals. They may cover the entire body (furred animals) or may be reduced to patches (man) or to scattered hairs (whales). Like scales and feathers, hairs are also cornified epidermal products of the integument. Collectively, all the hairs covering the body of a mammal, are known its *pelage*. It is periodically lost by moulting and replaced by a new one.

Each hair originates from the bottom of a tubular invagination, or *hair follicle*, of germinative layer of epidermis into dermis. A *dermal* or *hair papilla*, containing blood vessels and nerves, nourishes the swollen *root* or *bulb*, adding new cells forming the *shaft* of the hair. The cells of the shaft become keratinized, hardened and soon die, so that the hair protruding above the skin is a dead structure. It is lubricated by the only secretions of a *sebaceous gland* into follicle. A smooth arrector pili muscle is associated with each follicle. Typically, the hair shaft consists of three layers : an external *cuticle* made up of overlapping microscopic scales, middle *cortex* containing shrivelled cells and pigments, and inner *medulla* containing air spaces in larger hairs.

Chief functions of hairs seem to serve for insulation of body and as sensitive tactile organs (e.g. vibrissae). Hairs have several modifications (bristles, quills or spines, scales, horns, etc.) and variously used in industry.

Integument in Different Classes of Chordates

Although fundamental structure of skin remains similar in all vertebrates, yet variations occur in different classes involving : (i) presence or absence of dermal bones, (ii) relative abundance of glands in aquatic forms, and (iii) specializations of stratum corneum or surface layer of epidermis in terrestrial forms.

1. Lower chordates (Protochordata). In *Balanoglossus* and *Branchiostoma*, the integument or skin is quite simple and lacks keratin (Fig. 4). The outer epidermis is thin, made of a single layer of tall or columnar and often ciliated cells. Thus it is similar to that of invertebrates because it is stratified in all higher chordates. There are numerous unicellular epidermal gland cells, secreting a thin cuticle in amphioxus. Dermis or corium is gelatinous in amphioxus.

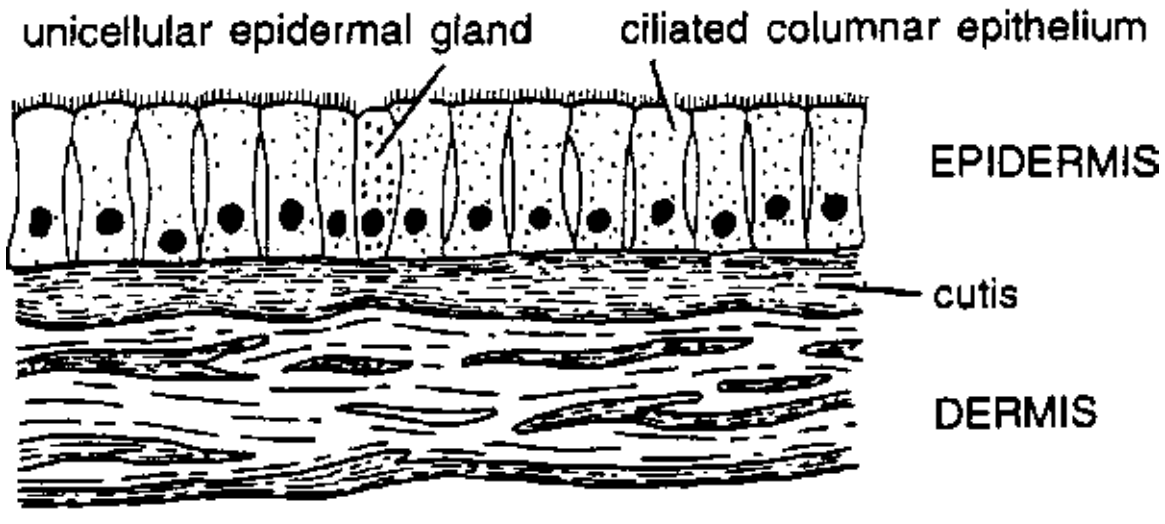

Fig. 4. Skin of a young *Amphioxus* in V. S.

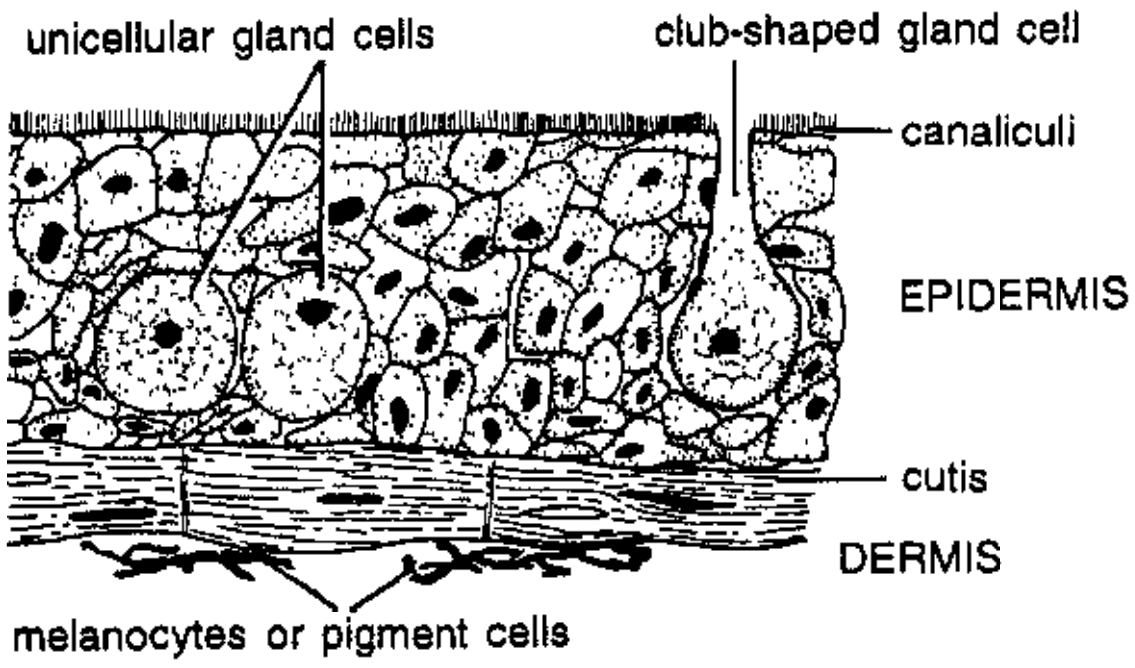

Fig. 5. Skin of a larval cyclostome in V. S.

2. Cyclostomata. Keratin does not occur in epidermis which differs from that of protochordates (*Branchiostoma*) but resembles that of higher chordates in being multi-layered and more durable (Fig. 5). Epidermis contains three types of secretory cells or unicellular glands : *mucous glands* secrete slime, elongated *club cells* with hyaline cytoplasm are probably neural or scab-forming, and *granular cells* are of unknown function. Below epidermis, a layer of collagen and elastic fibres forms *cutis*, which also contains star-shaped *pigment cells*. They have power of migration and also present in dermis.

3. Fishes. The epidermis is several-layered but simple, thin and without a typical stratum corneum

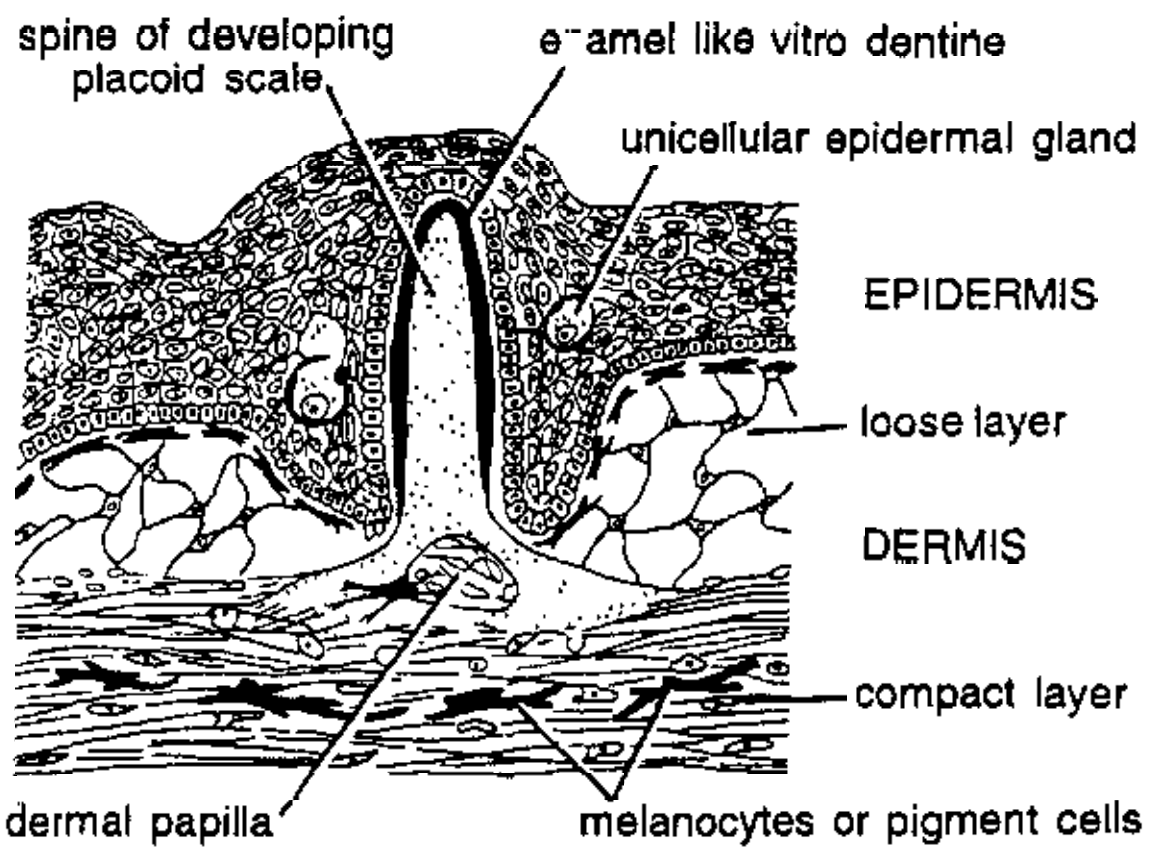

Fig. 6. Skin of dogfish embryo in V. S.

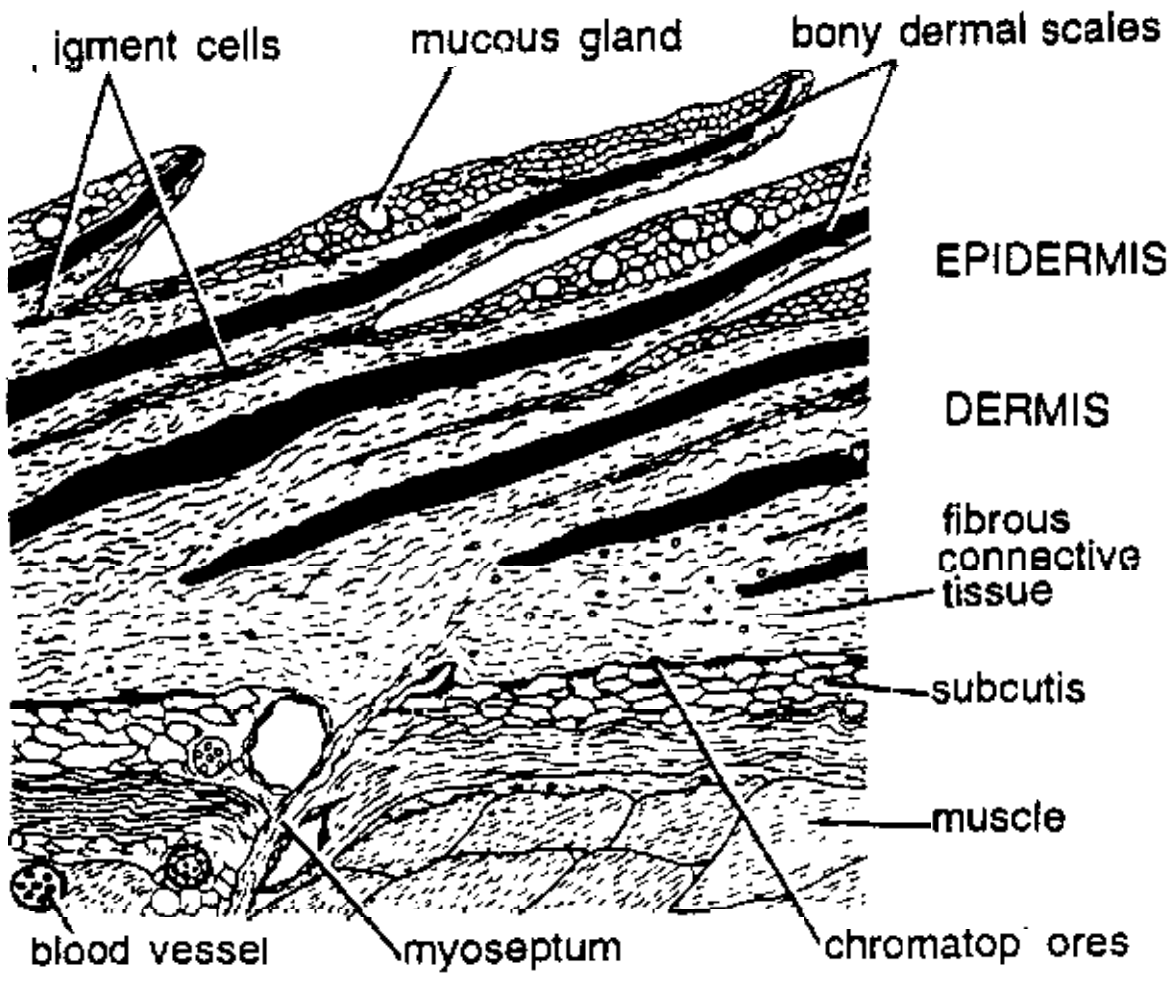

Fig. 7 Skin of a teleost fish in V. S.

as an adaptation to life in water (Figs. 6, 7 & 8). Epidermis is quite rich in unicellular *goblet* or *mucous gland cells* secreting mucous which reduces friction between body surface and water, protects from fungal or bacterial infections and controls osmosis. A few multicellular epidermal *glands*, such as *poison glands* and light-emitting organs or *photophores*, may also be found.

Dermis is typical but all the connective tissue fibres forming it run parallel to the surface. A peculiarity is the presence of atleast 5 types of *dermal scales* projecting above the surface. Of these cartilaginous fishes (elasmobranchs) have *placoid scales*. Chondrostei and Holostei have

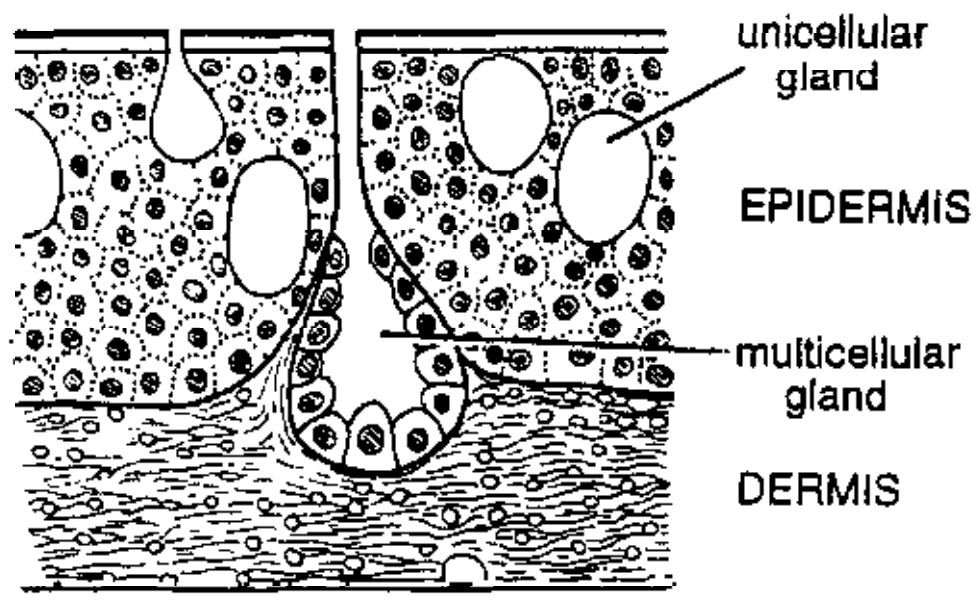

Fig. 8. Skin of a dipnoan (*Protopterus*) in V. S.

ganoid scales, while Teleostei have *cycloid* and *ctenoid scales*. *Cosmoid scales* are known from extinct Crossopterygii. Patterns and brilliance of colouration are perhaps greatest in fishes than in any other group of chordates. This is because of pigment cells called *chromatophores* and *iridophores* containing guanin, which are found in the dermis.

4. Amphibians. Typical amphibian skin is shown by frog (Figs. 9 & 10). It is thin and less intimately attached to the underlying muscles due [illegible] large *subcutaneous lymph spaces* beneath dermis. Typical amphibian skin is modified from that of fishes in atleast 3 primary respects. (i) In aquatic forms, stratified epidermis often exhibits a *thin stratum corneum* of flat and dead keratinized cells which are continuously being shed in patches and replaced. (ii) Amphibians are the lowest vertebrates having abundant *multicellular skin glands*, rather than unicellular. The mucous secreted keeps the skin moist and also permits respiratory gaseous exchange through richly vascular skin thus compensating for the poor development of lungs. However, the warty skin of land forms, such as toads, with heavier stratum corneum and less number of glands, resembles that of reptiles. Many amphibians have cutaneous *poison glands* (parotid glands of toad) whose toxic secretions serve toward off enemies. (iii) Skin of extinct Labyrinthodontia (stem Amphibia) was heavily armoured with *dermal scales* which are absent in modern Amphibia. However, remnants of dermal bony scales are found embedded in the skin of some

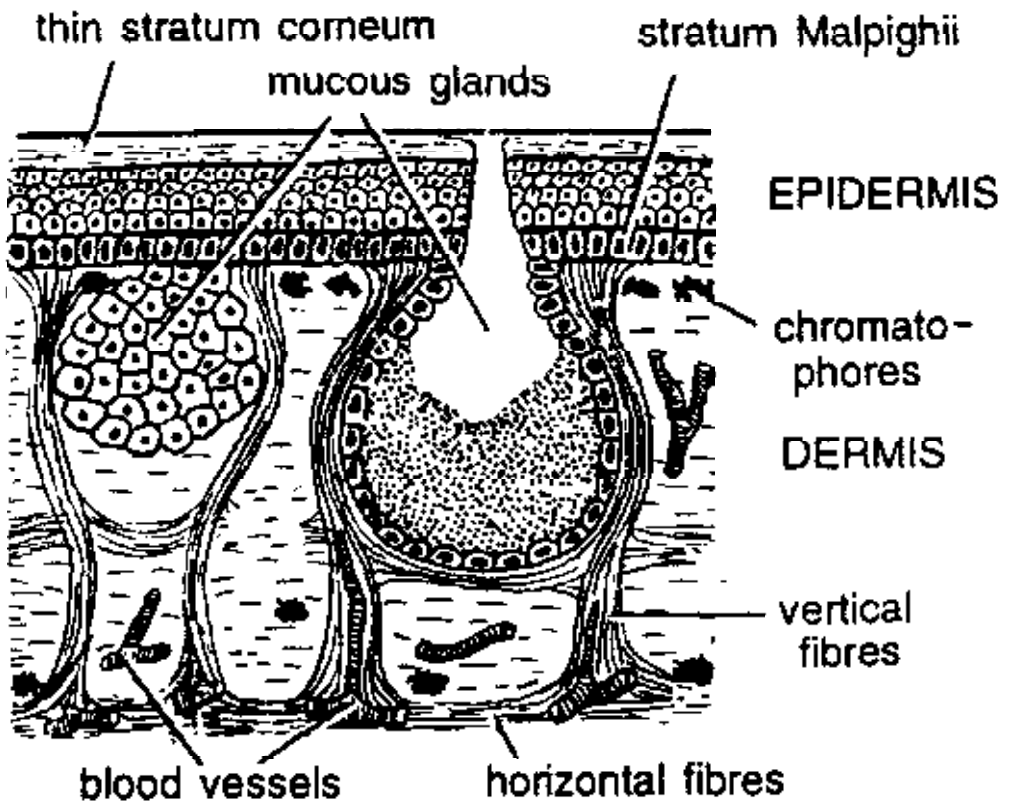

Fig. 9. Frog. V. S. skin.

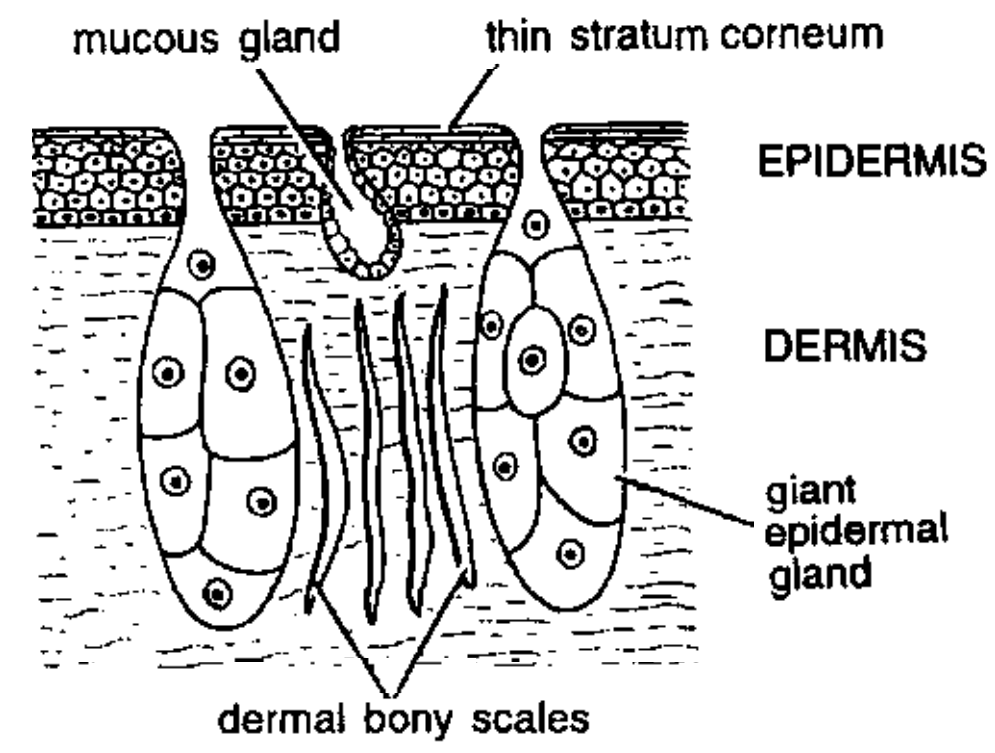

Fig. 10. *Ichthyophis*. V. S. Skin showing structure and dermal scales.

Gymnophiona and a few tropical toads. Some amphibians have the power to change body colour with the help of pigment cells or chromatophores present in dermis.

5. Reptiles. Reptiles are the first true land vertebrates and their integument shows many terrestrial adaptations (Fig. 11). (i) *Stratum corneum* is relatively thicker making the skin dry and prevent any loss of body moisture. It is variously modified to form overlapping horny *epidermal scales* covering the body, *spines, shields, scutes, plates, claws, horns, beaks, rattles* etc., forming the *exoskeleton*. These are periodically shed in small bits or even in a single piece (ecdysis or moulting). (ii) In addition to horny epidermal structures, reptiles also retain the bony dermal armour of their ancestors, in the form of *bony dermal scales, scutes* or *plates* called *osteoderms*, in their dermis. (iii) Reptiles exhibit relatively few *integumentary glands*, with the exception of *scent glands* for sexual attraction near cloaca in some snakes, *femoral glands* on the thighs of male lizards, and *musk glands* of musk-turtles and alligators. (iv) Some lizards and snakes exhibit elaborate *colour patterns* for concealment from predators and preys, or as warning signals. Some lizards (e.g. chamaeleons) have marked capacity to change their body colouration with the help of *chromatophores* present in dermis.

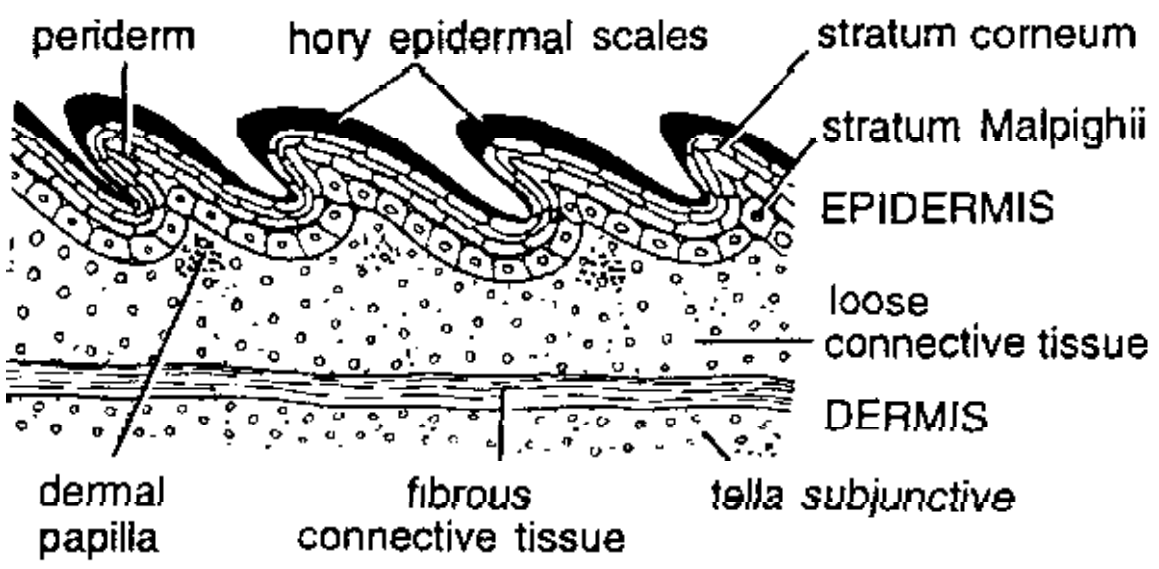

Fig. 11. Lizard. V. S. skin.

6. Birds. Skin of birds, Fig. 12 like that of other vertebrates, is composed of stratified epidermis and dermis. But, skin is thin and loosely attached to achieve maximum freedom of movement for flight. Modifications of stratum corneum, other than feathers, include horny sheaths of beaks. *Scales* are restricted to lower legs, feet, webs and base of beaks. *Claws* usually present on toes may also occur on one or two fingers (ostrich, hoatzin, geese, etc.). Like beaks, claws are also diversified and adapted to different habitats. Rest of the body is covered with *feathers* which undoubtedly evolved from epidermal scales. They protect and insulate the body. Feathers are shed and replaced seasonally. Three usual types of feathers are contour, down and filoplumes. No skin glands occur in birds with the exception of a *uropygial* or *preen gland* on tail, which is particularly well developed in aquatic birds. Its oily or waxy secretion is coated on feathers and beaks during preening. Bird skin has no chromatophores. *Melanocytes* containing pigments

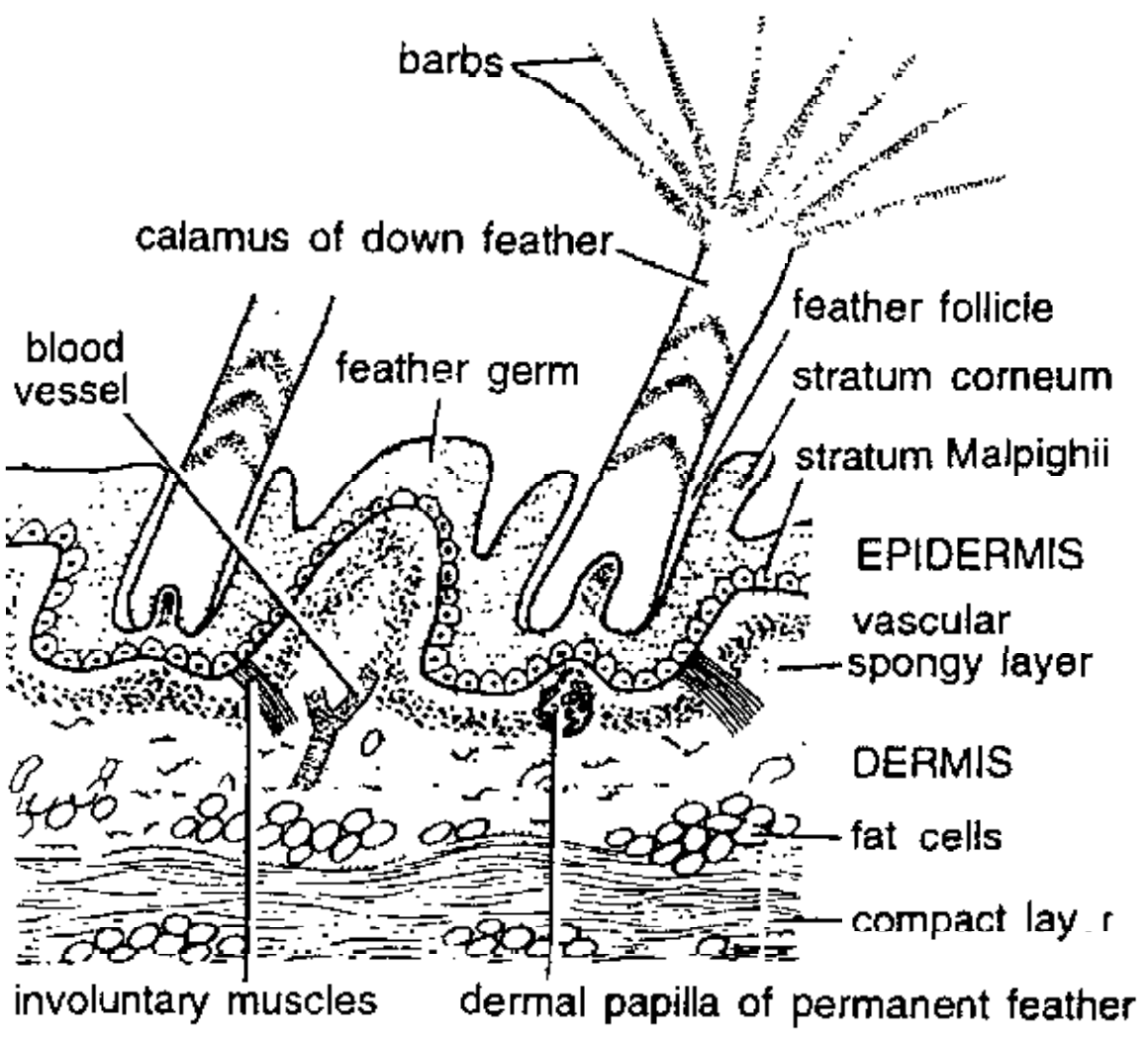

Fig. 12. Skin of a bird in V. S.

migrate into feathers and scales. Body colours are mainly due to reflection and refraction of light from feathers.

7. Mammals. Skin of mammals is elastic, water-proof, thickest of all vertebrates and variously modified (Fig. 13). The two layers, epidermis and dermis, have reached their highest specialization in mammals. The thick epidermis is differentiated into 5 layers from outside. These are *stratum corneum, stratum lucidum, stratum granulosum, stratum spinosum and stratum germinativum* or *Malpighian layer.* Stratum corneum containing keratin is particularly thicker on palms and soles having maximum friction and wear and tear. Modifications of stratum corneum include horny epidermal *scales, hairs, bristles, claws, nails, hoofs, horns,* etc.

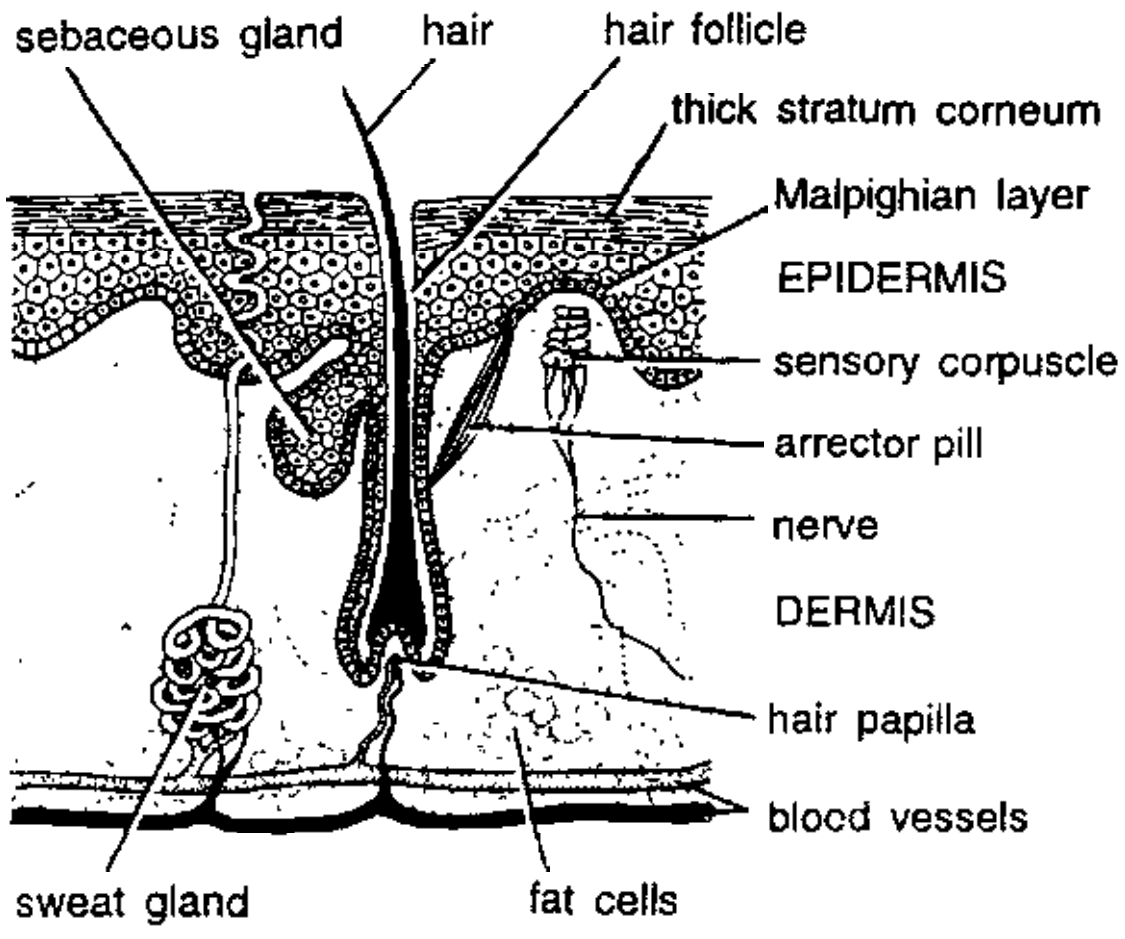

Fig. 13. Skin of a mammal in V. S.

Mammalian skin has a wide variety of *glands* which are all multicellular. Based on function there are 5 major types : *sebaceous, sweat, mammary, lacrimal* and *scent.* Of these mammary, sebaceous and sweat glands are found only in mammals. *Mucous glands* do not occur in the epidermis of mammals.

Dermis of mammals is proportionately much thicker than in other vertebrates. Except in armadillos, *dermal scales* do not occur in mammals. *Hair colour* is due to the presence of varying intensities of brown or black pigment granules between and within the hair cells. *Skin colour* is due to varying concentrations of melanin granules in basal layers of epidermis, or due to pigment-containing melanocytes located in dermis just beneath the epidermis. *Albinism* results from lack of pigments, while *melanism* results from the presence of an excess of black pigments.

IMPORTANT QUESTIONS

» *Long Answer Type Questions*

1. What is integument? Describe the integument and its derivatives in vertebrates.
2. Give an account of the integument in vertebrate you have studied and explain its functions.
3. Discuss how the integuments of reptiles and birds are adapted to their respective modes of life.
4. Give a comparative account of integument of reptiles, birds and mammals.
5. Describe the exoskeletal structures in vertebrates you have studied.

» *Short Answer Type Questions*

1. Draw labelled diagram of vertical section of the skin of — (i) Lizard, (ii) Bird, (iii) Frog, (iv) Mammals.
2. Write notes on — (i) Epidermal glands, (ii) Horns, (iii) Keratinization, (iv) Osteoderms.

» *Multiple Choice Questions*

1. Study of structure of animals :
   (a) Anatomy (b) Histology
   (c) Morphology (d) Physiology
2. Outermost protective covering of animals :
   (a) Feathers (b) Integument
   (c) Scales (d) Hairs
3. Which is not a function of skin?
   (a) Protection (b) Locomotion
   (c) Secretion (d) Digestion
4. Integumentary gland secreting tears :
   (a) Mammary gland (b) Sebaceous gland
   (c) Lacrymal gland (d) Uropygial gland
5. In presence of sunlight vitamin D is synthesized in mammalian skin from :
   (a) Sweat (b) Earwax (c) Sebum (d) Tears
6. Dermis of vertebrate integument is derived from :
   (a) Ectoderm (b) Mesoderm
   (c) Endoderm
   (d) Ecto-mesoderm
7. Melanocytes are located in :
   (a) Stratum corneum
   (b) Stratum germinativum
   (c) Stratum lucidum
   (d) Dermis
8. Poison secreted by parotid glands of amphibians is :
   (a) Alkaloid (b) Alcohol
   (c) Fatty acid (d) Carbohydrate
9. Reflecting pigment cells in luminescent glands contain :
   (a) Guanine crystals (b) Adenine crystals
   (c) Cytosine crystals (d) Thymine crystals
10. In birds uropygial gland is present just above the :
   (a) Beak (b) Eye (c) Tail (d) Ear
11. In Hippopotamus, sweat glands are restricted to :
   (a) Ears (b) Muzzle
   (c) Lips (d) Soles of feet
12. Digital cornifications are modifications of :
   (a) Stratum corneum (b) Stratum germinativum
   (c) Stratum lucidum (d) Dermis

ANSWERS

1. (a) 2. (b) 3. (d) 4. (c) 5. (c) 6. (b) 7. (d) 8. (a) 9. (a) 10. (c) 11. (a) 12. (a)

52

Endoskeleton in Vertebrates

What is Skeleton?

The hardened tissues of the body together form the *skeleton* (*sclero* = hard). Organism will remain small and slow moving if there had been no skeleton for support and to serve as levers on which muscles can act. Skeleton of invertebrates is most often secreted on the surface, forming a lifeless or dead *exoskeleton*. Whereas skeleton of vertebrates develops most often underneath the surface forming a living or growing *endoskeleton*.

Types of Vertebrate Skeletons

Three types of skeletons develop in vertebrates :

1. Epidermal horny exoskeleton. These include hard and horny or keratinized derivatives of epidermal layer of skin, such as claws, reptilian scales, bird feathers and mammalian hairs, horns, nails and hoofs, etc. All living amphibians lack an exoskeleton. Epidermal horny exoskeletal structures of vertebrates have already been discussed in Chapter 51.

2. Dermal bony skeleton. Dermal bony skeleton is derived from the dermis of skin. It includes bony *scales* and *plates* or *scutes* (*osteoderms*), *finrays* and *antlers* of fishes, reptiles and mammals. In fishes, dermal scales become exposed due to wearing out of epidermis, and form exoskeleton.

3. Endoskeleton. Greater part of vertebrate skeleton lies more deeply, forming the endoskeleton. It develops from mesenchyme. At early embryonic stage, endoskeleton is composed of *cartilage*, which is replaced by *bone* in most adult vertebrates. Such bones deposited in place of preexisting cartilages, are called *cartilage* or *replacement bones*. Thus, they are distinguished from the *dermal* or *membrane bones* which directly form more superficially in dermis without any preexisting cartilage. Despite this difference in the mode of their development, the two types of bones are similar histologically.

Functions of Endoskeleton

Chief functions of vertebrates can be enumerated as follows :

(1) To provide physically support to body by forming a firm and rigid internal framework.
(2) To give definite body shape and form.
(3) To protect by surrounding delicate internal organs like brain, heart, lungs, etc.
(4) To permit growth of huge body size (whale, elephant, extinct dinosaurs), since it is living and growing.
(5) To provide surface for attachment of muscles.
(6) To serve as levers on which muscles can act.
(7) To manufacture blood corpuscles in bone marrow.
(8) To aid in hearing (ear ossicles).
(9) To help in breathing (tracheal rings, ribs).

Subdivisions of Vertebrate Endoskeleton

For convenience of study, endoskeleton of vertebrates is further subdivided into 3 major categories on the basis of their location in body—axial, appendicular and heterotopic. Each of these categories includes several elements as given in Table 1.

According to another scheme, endoskeleton can be divided first into somatic and visceral skeletons, as follows :

1. Somatic skeleton. Skeleton of body wall.

(a) ***Axial skeleton.*** Vertebral column, ribs, sternum and most of the skull (neurocranium and dermatocranium).

(b) ***Appendicular skeleton.*** Girdles and limb bones.

2. Visceral skeleton. Skeleton of pharyngeal wall (splanchnocranium).

Skull

The skeletal structure forming the framework of the vertebrate head is called *skull*. It is an important structure which is derived from three

Table 1. **General Divisions of Endoskeleton in a Land Vertebrate.**

I. Axial skeleton (median)			**II. Appendicular skeleton (lateral, paired)**		**Heterotopic bones (miscellaneous)**
Skull	**Vertebral column**	**Thoracic basket**	**Girdles**	**Limb bones**	**Develop in association with certain organs**
A. **Neurocranium** 1. Cranium or brain box surrounding brain 2. Sense capsules (i) *Olfactory*–nose (ii) *Optic*–eyes (iii) *Auditory* ears	**Vertebrae** 1. Cervical–neck 2. Thoracic–chest 3 Lumbar–lower back 4. Sacral–hip 5. Caudal–tail	**A. Ribs** Paired; bony or cartilaginous **B. Sternum** Breast bone	**A. Pectoral** Anterior or shoulder girdle. Includes : 1. Scapula–dorsal 2. Clavicle–anterior 3. Coracoid–posterior	**A. Forelimb** 1. Humerus-upper arm 2. Radius and ulna-forearm 3. Carpals-wrist 4. Metacarpals-palm 5. Phalanges-fingers	**1. Os cordis**—Inter ventricular septum of heart in deer and bovines **2. Rostral**– Pig's snout
B. **Dermatocranium** Membrane or dermal bones of skull C. **Splanchnocranium** Includes visceral arches or pharyngeal skeleton 1. Upper jaw 2. Lower jaw 3. Hyoid 4. Larynx			**B. Pelvic** Posterior or hip girdle. Includes : 1. Ilium-dorsal 2. Pubis-anterior 3. Ischium-posterior	**B. Hind limb** 1. Femur– thigh 2. Tibia & fibula–shank 3. Tarsals– ankle 4. Metatarsals–sole 5. Phalanges – toes	**3. Os penis**–Penis of bats, rodents, marsupials, carnivores, insectivores, whales, lower primates. **4. Os clitoridis**–Clitoris of otters, rabbits, several rodents. **5. Pessulus**–Syrinx of birds. **6. Epipubic**–Ventral abdominal wall of monotremes and marsupials. **7. Sesamoid**–Pisciform in hand, patella (kneecap), etc.

major embryonic components— (i) *neurocrancium* or *chondrocranium*, (ii) *dermatocranium* and (iii) *splanchnocranium.*

1. Neurocranium or chondrocranium. It includes (i) the *cranium* or *brain box* that houses the brain, and (ii) three pairs of *sense capsules* containing special sense organs of smell (*olfactory*), sight (*optic*) and hearing (*otic*).

2. Dermatocranium. It includes membrane or dermal bones attached to neurocranium and splanchnocranium.

3. Splanchnocranium. It includes the visceral or pharyngeal skeleton, originally forming a series of paired arches providing jaws, support for tongue (hyoid), and support for gill region.

Table 2 lists all the different types of bones found in different regions in the skull of vertebrates.

***Table** 2.* **Types of Bones in Skull of Vertebrates.**

Region of skull	Cartilage or replacement bones	Membrane or dermal bones	Bones of mixed origin
A. Chondrocranium 1. *Occipital*	* Supraoccipital Exoccipital * Basioccipital	Parietal * Interparietal Postparietal	
2. *Parietal*	* Basisphenoid Pleurosphenoid		
3. *Frontal*	Orbitosphenoid * Presphenoid	Frontal Postfrontal Lacrimal	Prefrontal
4. *Olfactory capsule*	* Mesethmoid Turbinals } Cribriform } Ethmoid Ectethmoid	Nasal Vomer Septomaxillary	
5. *Otic capsule*	Epiotic Prootic Opisthotic	Squamosal Supratemporal	Sphenotic Pterotic
6. *Optic capsule*	Sclerotic		
7. *Palate*		* Parasphenoid Vomer (in mammals) Endopterygoid or Pterygoid Ectopterygoid	Palatine
B. Splanchnocranium *1. Upper jaw*	Quadrate (incus) Epipterygoid Alisphenoid Metapterygoid	Premaxilla Maxilla Jugal Quadratojugal	
2. *Lower jaw*	Articular (malleus) Mentomeckelian	Dentary (mandible) Coronoid Splenial Angular Supra angular	
3. Hyoid arch	Hyomandibular Columella (stapes) Symplectic Inter- epi-, hypo-, cerato-, * basihyal		
4. Gill cover		Preopercular Opercular Subopercular Interopercular Gular	

N.B.—All bones are paired. Single bones are marked with an asterisk (*).

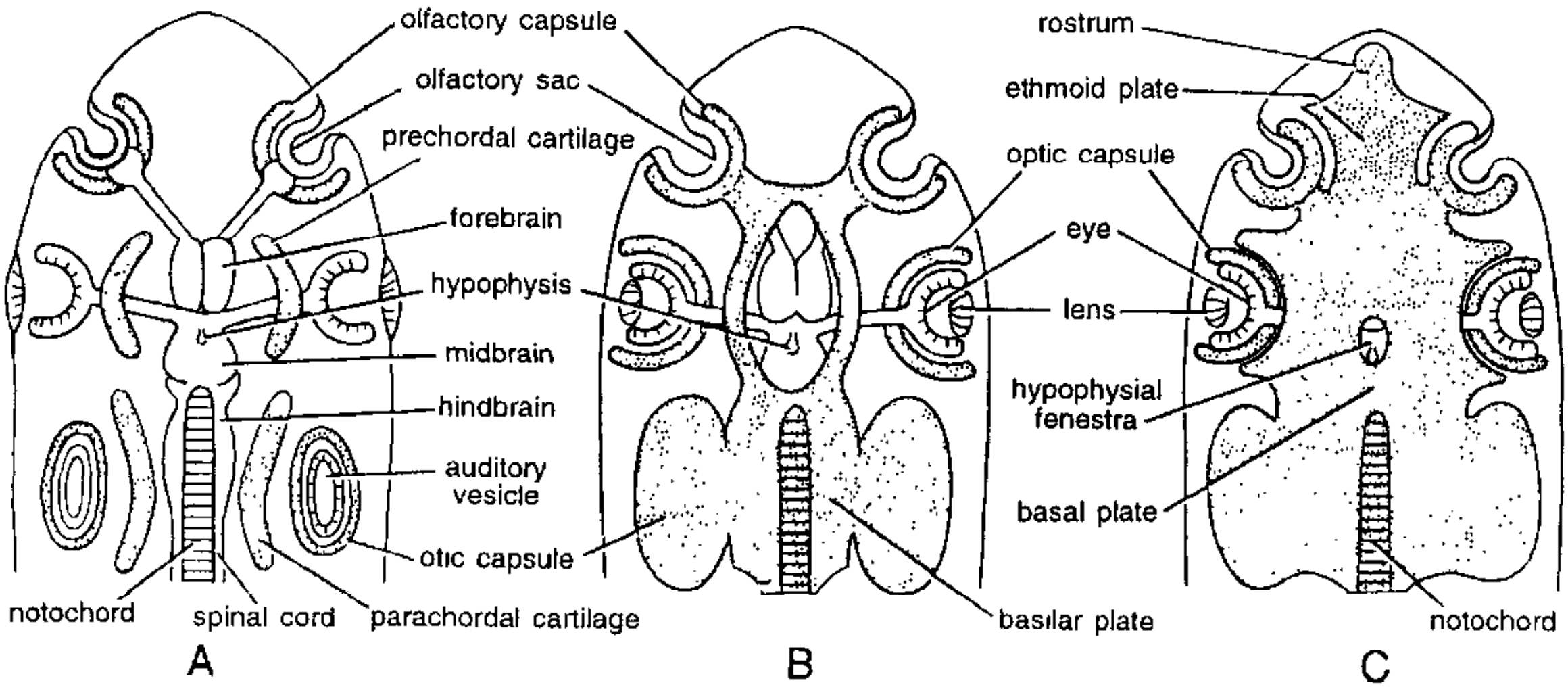

Fig. 1. Stages to show diagrammatic development of chondrocranium or cartilaginous neurocranium in ventral view A—Cartilages appear in head of embryo B—Formation of ethmoid and basilar plates. C—Chondrocranium completed

[I] Morphogenesis (history and development) of skull

1. Development of chondrocranium. Skull formation commences in the embryo soon after the formation of central nervous system and notochord (Fig. 1). A pair of curved cartilaginous plates, called *prechordals*, forms parallel to and below the forebrain. Similarly, another pair of *parachordal cartilages* forms beneath the midbrain and hindbrain, and parallel to the anterior end of notochord. The two prechordals expand towards each other and unite in the midline to form an *ethmoid plate*. Similarly, the two parachordals unite across the midline forming a *basilar plate*. Later, the ethmoid and basilar plates also grow towards each other and fuse to form a single *basal plate*, or floor upon which the brain rests. A large opening in the basal plate, the *hypophyseal fenestra*, lodges the pituitary gland.

Meanwhile, paired capsules of cartilage are also formed around the developing sense organs. The *olfactory capsules* around the nasal epithelium, and *auditory* or *optic capsules* surrounding the membranous labyrinths or internal ears, fuse with the basal plate forming the *neurocranium*. In its cartilaginous stage, the neurocranium is often termed *chondrocranium*, which means 'cartilaginous braincase'. The *optic capsules* or *sclerotic coats* around the eyes do not fuse with the chondrocranium, so that eyeballs can move independently of skull.

Further development involves formation of cartilaginous walls along lateral sides of brain. In lower forms, such as elasmobranches and lower bony fishes (e.g. *Amia*), the sidewalls further grow forming a complete cartilaginous roof over brain. Some openings remain uncovered for cranial nerves and blood vessels. The largest of all is foramen magnum at the posterior end of chondrocranium for spinal cord. In most bony fishes and tetrapods, however, the brain is not roofed over by cartilage except above the foramen magnum. Later membrane or dermal bones form a roof over the brain.

2. Development of splanchnocranium. It develops partly from neural crest cells and from splanchnic mesoderm. It includes visceral or pharyngeal skeleton consisting of a series of horseshoe-shaped paired cartilaginous arches (usually 7 pairs) encircling and supporting the pharynx between gill clefts. The arches remain united and interconnected ventrally, but are free dorsally. In jawed vertebrates or gnathostomes, the *first* or *mandibular arch* on either side is divided into a dorsal *palatopterygoquadrate cartilage* forming the *upper jaw*, and a ventral *Meckel's cartilage* forming the *lower jaw*. The *second* or *hyoid* arch on either side gives out a dorsal *hyomandibular* cartilage to support and connect jaws to chondrocranium below auditory region, and ventrally forming the *hyoid apparatus* supporting tongue. The remaining or *branchial arches* support the gills or larynx.

[II] Skull in different vertebrates

A comparative study shows that the basic architectural pattern of the three major components of skull (viz., neurocranium, dermatocranium and splanchnocranium) is essentially the same in all the vertebrates. However, there are many differences in general form and detailed structure of skull, including reduction in the number of bones.

1. Cyclostomata. Skull is most primitive (or specialized?) among living cyclostomes. It retains cartilaginous embryonic neurocranium with an imperfect fibrous roof without dermal plates or bones. Visceral skeleton, modified as a branchial basket, is not comparable with that of higher vertebrates.

2. Chondrichthyes. In elasmobranchs, neurocranium is cartilaginous. Brain is completely roofed. Olfactory and otic capsules are fused with the chondrocranium, but optic capsules remain free. Dermal bones are absent.

3. Osteichthyes. In ganoids or primitive bony fishes, such as gar, sturgeon, spoonbill, *Amia*, etc. and earlier crossopterygians, neurocranium is flat,

Table 3. **Major Skeletal Derivatives of Visceral Arches in Representative Vertebrates.**

Visceral arch	Dogfish (*Scoliodon*)	Teleost (Bony fish)	Amphibian (*Necturus*)	Amphibian (Frog)	Reptile & Bird (*Uromastix* & Pigeon)	Mammal (Rat or rabbit)
I.	Meckel's cartilage	Articular	Articular	Articular Mentomeckelian in some species	Articular	Malleus
	Pterygoquadrate	Quadrate Epipterygoid Metapterygoid	Quadrate Cartilage in lateral Roof of mouth	Quadrate Annulus tympanicus	Quadrate Epipterygoid —	Incus Alisphenoid —
II.	Hyomandibula	Hyomandibula	Rudimentary	Columella	Columella	Stapes
		Symplectic	—	—	—	—
	Ceratohyal	Interhyal	Ceratohyal	Anterior horn	Anterior horn	Anterior horn
		Epihyal	—	—	—	—
		Ceratohyal	—	—	—	—
	Basthyal	Hypohyal Entoglossal	Hypopyal	Body of hyobranchial apparatus	Body of hyobranchial apparatus Entoglossus	Body of hyoid
III.	Pharyngobranchial Epibranchial Ceratobranchial Hypobranchial	Pharyngobranchial Epibranchial Ceratobranchial Hypobranchial	Epibranchial Ceratobranchial	Body of hyobranchial apparatus	Second horn Body of hyobranchial apparatus	Posterior horn Body of hyoid
IV.	Branchial elements (as in III)	Branchial elements (as in III)	Branchial elements (as in III)	Posterior horn Body of hyobranchial apparatus	Posterior horn	Thyroid cartilage
V.	Branchial elements	Branchial elements	Epibranchial only Homologies of laryngeal cartilages remain in doubt	Not clearly delineated		Thyroid Cricoid Arytenoid
VI.	Branchial elements	Branchial elements	Missing or not clearly delineated			
VII.	Bears no gill Some reduction	Reduced	Missing			

completely roofed, cartilaginous and partially ossified forming many sculptured dermal bones by the fusion of dermal scales. In *Polypterus*, neurocranium is extensively ossified.

In some primitive teleosts (trout, salmon), chondrocranium is mostly cartilaginous. But, in higher teleosts, skull is highly specialized, laterally compressed and well ossified. Dermal bones are smooth, without ganoin, and not scale-like. Cartilaginous visceral arches have been changed to bones or replaced by dermal bones. Palatoquadrate cartilages do not meet anteriorly. Upper jaw is formed by premaxilla and maxilla, which are dermal bones. Lower jaw (Meckel's cartilage) has three bones—dentary, angular and articular-the last hinging on quadrate which attaches to cranium.

4. Amphibia. Modification in skull of Amphibia over that of fishes are correlated with the shift from water to land. There are fewer bones and much more embryonic cartilage in skull of modern amphibians, which is markedly platybasic and flattened. Basioccipital, supraoccipital, basisphenoid and presphenoid are absent. Hyomandibular becomes columella of the middle ear. Ventral wall of otic capsule bears a membrane covered aperture, fenestra ovalis, into which columella articulates for transmitting sound waves. Two occipital condyles, one on each exoccipital, are present. Visceral skeleton is essentially bony fish-like except that the number of gill-bearing arches is reduced.

5. Reptilia. In modern reptiles, neurocranium shows extensive ossification except in naso-ethmoidal region. There is one occipital condyle and more dermal bones than in Amphibia. Skull is tropibasic. One or two temporal fossae occur behind the orbits, except in Chelonia. Pineal foramen is lost, except in *Sphenodon* and many lizards. Prootic, epiotic and opisthotic of otic region remain separate. A quadratojugal is absent. Quadrate is movable at both ends showing streptostylism. There is tendency to form a Turbinal element in nasal passage, and to form a secondary palate. A transverse ectopterygoid and a vertical epiterygoid are present. Hyomandibular is modified into columella of middle ear. Lower jaw exhibits a large toothed dentary, angular, supraangular, splenial, coronoid and articular bones.

6. Aves. Bird skull is essentially reptilian in structure. Neurocranium is well ossified. A single occipital condyle occurs. Modifications are associated with flight and altered feeding habits. Skull is large, penumatic and light, with very thin dermal bones and practically without sutures. Premaxillary and dentary are elongated to form a toothless beak necessary for feeding. Cranium is large and its roof domed to accommodate the larger brain. Orbits are large, separated by a thin interorbital septum, and each with a ring of dermal sclerotic bones. Foramen magnum faces downwards. Like reptiles, there is a columella in the middle ear. Quadrate is streptostylic. Lower jaw has one cartilage bone (articular) and four dermal bones.

7. Mammalia. Mammalian skull has two occipital condyles, a condition inherited from ancestral synapsid reptiles. Prefrontals, postfrontals, transpalatines, supraorbitals, postorbitals, parasphenoid, quadratojugals, quadrates and all lower jaw bones except dentary are absent. Occipital bones fuse into a single piece enclosing foramen magnum. Otic bones become fused into a petrosal or periotic. Middle ear cavity has 3 ear ossicles - malleus (articular), incus (quadrate) and stapes (columella or hyomandibula). A complete secondary palate is present. Teeth are heterodont and present on premaxillae, maxillae and dentaries. Pterygoids are insignificant. Lower jaw on either side is made of a single dentary, there being no trace of Meckel's cartilage. Hyoid arch mainly contributes to hyoid apparatus. Remaining visceral arches contribute to thyroid, epiglottis, arytenoids, cricoid, tracheal rings, etc.

[III] Suspensoria or jaw suspensions

As mentioned earlier, the vertebrate skull has three major parts - neurocranium, dermatocranium and splanchnocranium. The splanchnocranium includes the visceral arches. The first or *mandibular arch* consists of a dorsal *palatopterygoquadrate bar* forming the upper jaw, and a ventral *Meckel's*

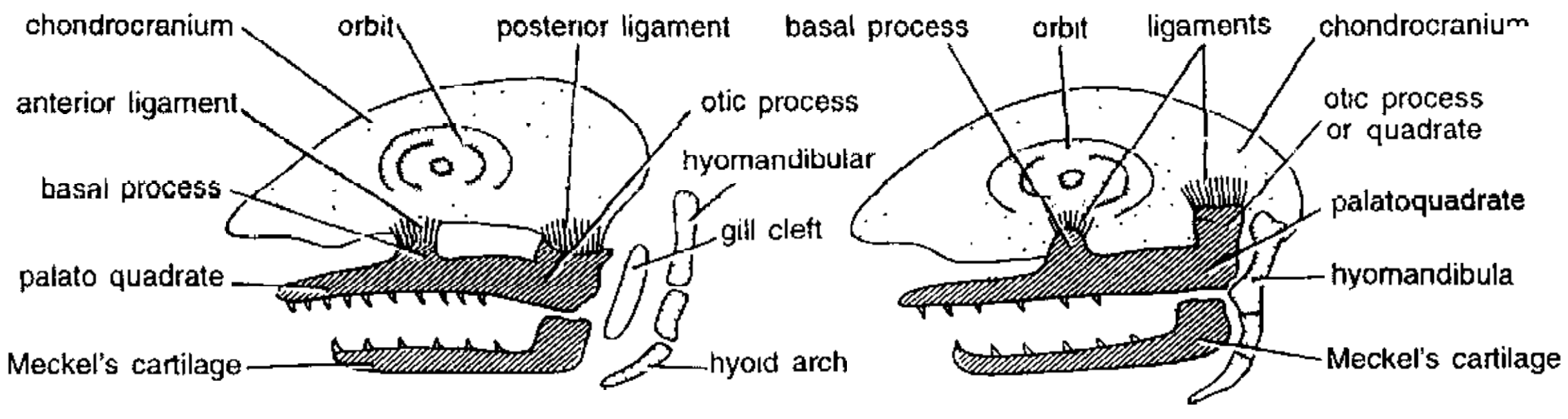

AUTODIASTYLIC AMPHISTYLIC

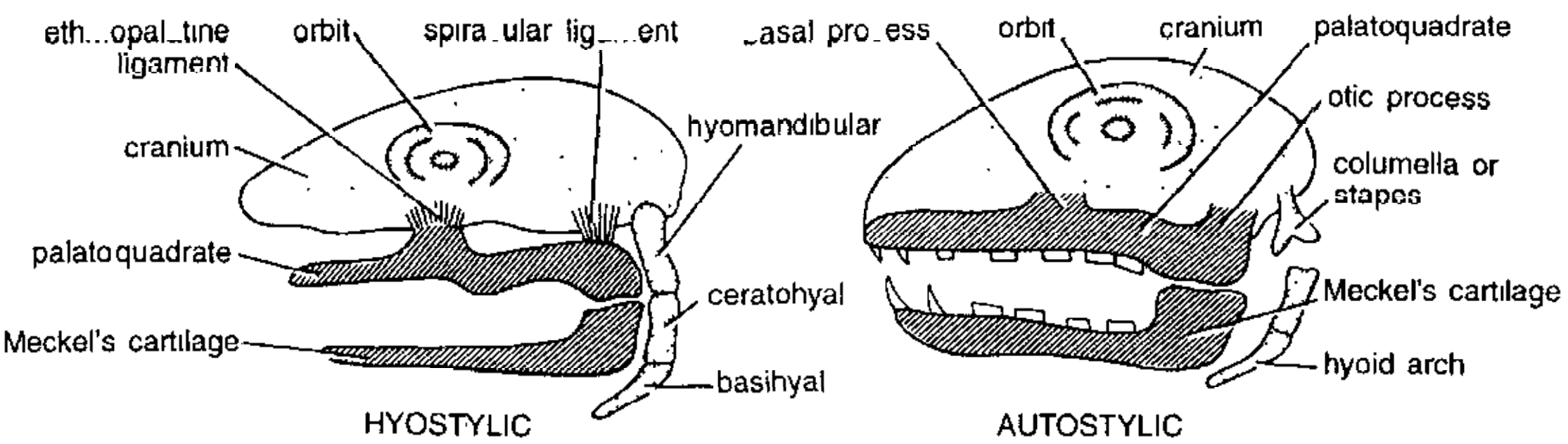

HYOSTYLIC AUTOSTYLIC

Fig. 2. Types of jaw suspensoria in vertebrates

cartilage forming the lower jaw. The second or *hyoid arch* consists of a dorsal *hyomandibular* which supports and suspends the jaws with the cranium, and a ventral *hyoid proper.* The remaining arches support the gills and are known as branchial arches.

Thus, we find that splanchnocranium plays an important role in the formation of jaws in gnathostomes, and in their suspension with the chondrocranium. The method of attachment or suspension of jaws from the chondrocranium is termed *jaw suspension* or *suspensorium*. There are 5 principal variants or types of suspensoria as follows (Fig. 2) :

1. Autodiastylic. This condition was found in some earliest gnathostomes such as acanthodians. The jaws are attached to the cranium by anterior and posterior ligaments. Hyoid arch remains completely free or independent and does not support the jaws. The gill cleft in front of hyoid arch bears a complete gill and does not form any spiracle.

2. Amphistylic. This is a rather primitive arrangement found in Crossopterygii and some primitive sharks (e.g. *Heptanchus, Hexanchus*). The quadrate or the basal and otic processes of upper jaw (mandibular arch) are attached by ligaments to chondrocranium. Similarly, the upper end of hyomandibula (hyoid arch) is also attached to chondrocranium, while the two jaws are suspended from its other end. This arrangement makes a double suspension (*amphi* = both+*style* = bracing) since both the first and second arches participate in bracing the jaws against the chondrocranium.

3. Hyostylic. It is found in most elasmobranchs and all bony fishes. Upper jaw (palatoquadrate) is loosely attached by anterior ethmopalatine to cranium. Both the jaws are braced against hyomandibular, the upper end of which fits into auditory region of skull. Since only hyoid arch braces or binds the two jaws against cranium, this jaw-suspension is termed *hyostylic*. It provides the jaws a wider movement and helps in swallowing larger preys.

4. Autostylic. This condition is found in extinct placoderms, chimaeras, lung fishes and most tetrapods (amphibians, reptiles and birds). Hyomandibular does not participate but becomes modified into columella or stapes of middle ear for transmitting sound waves. Upper jaw (palatoquadrate) is directly and intimately bound to cranium by investing dermal bones (*auto* = self). The articular of lower jaw articulates with the quadrate of the upper jaw.

Autostylic suspensorium is widespread and has at least 3 variation or subtypes.

(a) Holostylic. In Holocephali (chimaeras), upper jaw is firmly fused with skull and lower jaw suspended form it. Hyoid arch is complete, independent and not attached to skull.

(b) Monimostylic. In many tetrapods, hyomandibular forms columella and articular articulates with quadrate. However, the quadrate remains immovably attached with skull.

(c) Streptostylic. In some reptiles (lizards, snakes) and birds, quadrate is loosely attached and is movable at both ends, a condition known as *streptostylism.*

5. Craniostylic. This type of jaw-suspension is characteristic of mammals and some consider it as a modification of autostylic suspension. Upper jaw fuses throughout its length with cranium, and hyomandibular forms the ear ossicle stapes. But articular and quadrate also become modified into ear ossicles malleus and incus, respectively. Consequently, two dermal bones, dentary of lower jaw and squamosal of skull, provide the articulation between jaw.

Vertebral Column

Notochord. In all chordate embryos, the first axial endoskeleton to appear is a slender, stiff, unsegmented, gelatinous rod, the *notochord.* It is present below the nerve cord and above the digestive tract. Its ancestral predecessor is not known but it probably originated from endoderm. Typically, notochord is covered by inner and outer elastic fibrous connective tissue sheaths, called *elastica interna* and *elastica externa,* respectively.

In protochordates (amphioxus) and cyclostomes (lamprey), notochord persists throughout life and continues to grow with the animal. But in fishes and higher types, notochord is later on surrounded by cartilaginous or bony rings, called *vertebrae.* In most fishes and aquatic amphibians, the adult notochord is constricted within each vertebra. It is not constricted in lungfishes and sturgeon. In tetrapods, it is practically obliterated.

Vertebrae. Backbone or vertebral column of all vertebrates is formed of a metameric series of many small and essentially similar pieces, called *vertebrae.* Thus, a vertebra is the unit of vertebral column. Vertebrae are named after the region of body in which they occur. Vertebral column of fishes comprises only *trunk* (abdomen) and *caudal* (tail) vertebrae (Figs. 3A–B). In tetrapods, vertebral column includes five regions : *cervical,*

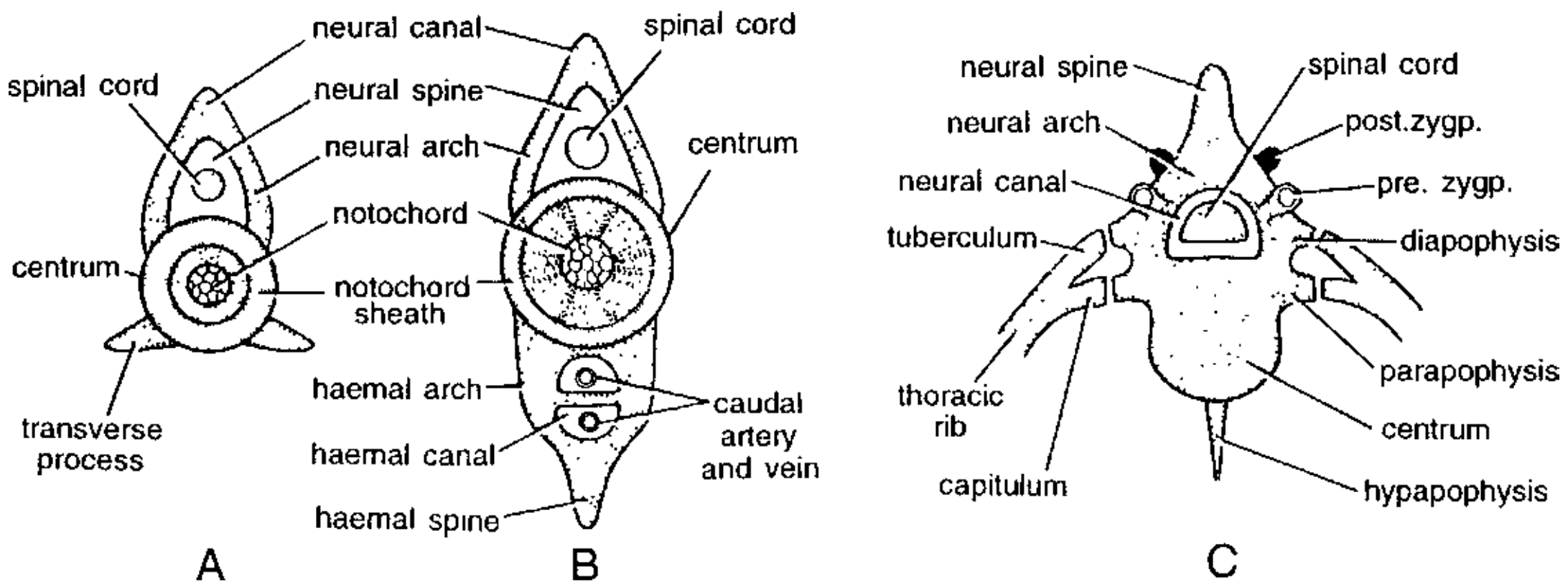

Fig 3 Structure of a vertebra showing processes in cephalic view. A—Trunk vertebra of shark. B—Caudal vertebra of shark C—Typical tetrapod vertebra

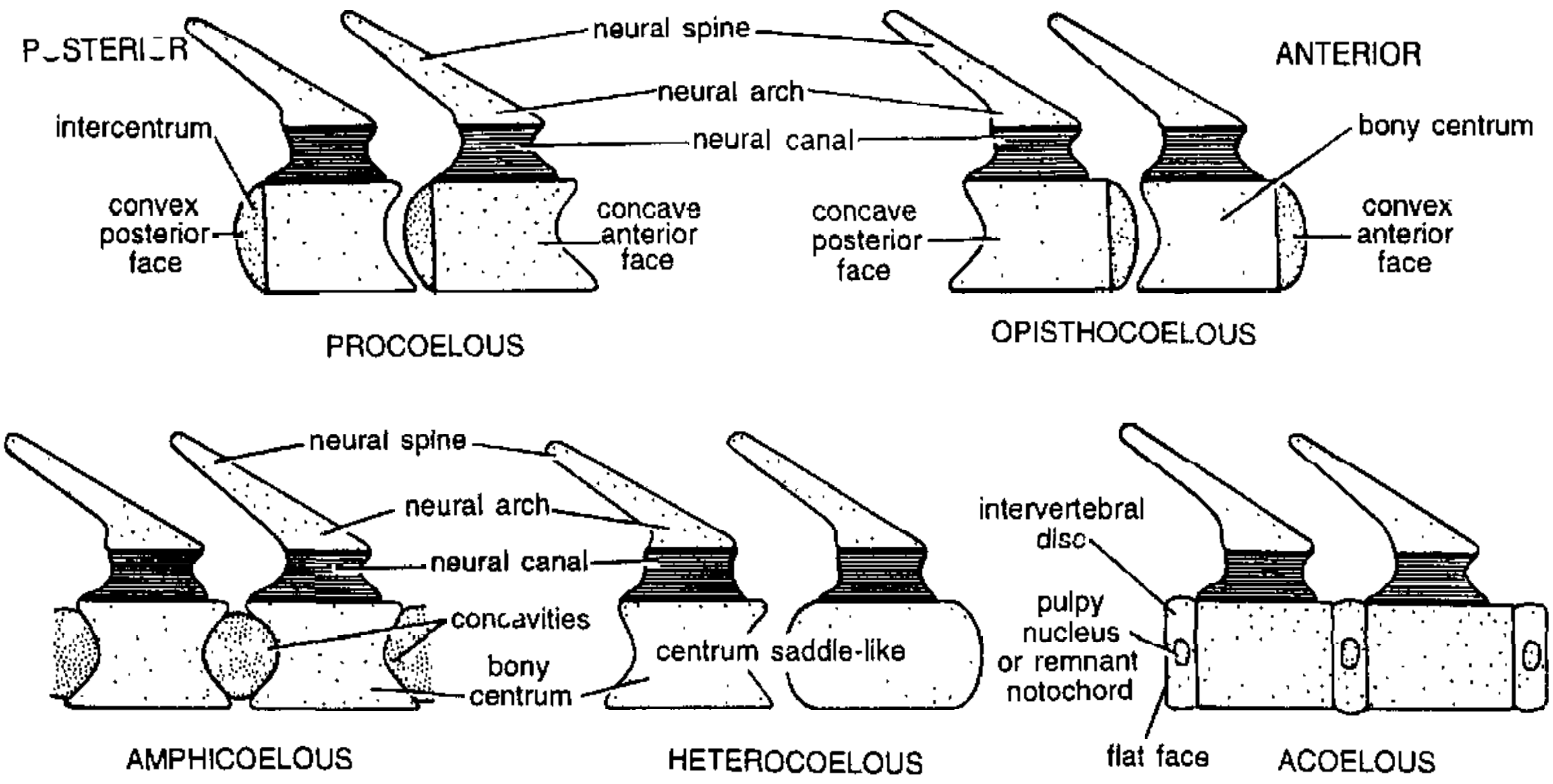

Fig. 4. Types of vertebrae based on shape of centra, in sagittal section.

thoracic, lumbar, sacral and *caudal*, each having usually several vertebrae. Amphibians have a single cervical (atlas) and only one sacral (9th) vertebra. Morphologically, vertebrae differ in different vertebrates or even in different regions of the same vertebrate, but all vertebrae are built according to a similar basic pattern.

Basic structure of a vertebra. Typically, a vertebra has a cylindrical, spool-like body or *centrum*, which encloses or replaces the embryonic notochord (Fig. 3C). Above the *centrum* is a *neural arch* produced dorsally into a *neural spine*. Successive neural arches enclose a *vertebral* or *neural canal* in which the *spinal cord* lies. The caudal vertebra in fishes also has a ventral *haemal arch* enclosing a *haemal canal* through which the caudal artery and vein pass. Haemal arch also carries a ventral *haemal spine*.

Types of processes. Various kinds of processes (*apophyses*) arise from the arches or centra of vertebrae.

(a) ***Zygapophyses.*** In vertebrates, from anterior and posterior faces of neural arch project paired articular facets, the *pre-* and *post- zygapophyses*. These serve for articulation between adjacent vertebrae. Zygapophyses do not occur in fish vertebrae.

(b) ***Transverse processes.*** Lateral transverse processes arise from centrum and serve for attachment of ligaments and muscles.

(c) ***Diapophyses.*** Each projects laterally from centrum or neural arch and articulates with dorsal head (tuberculum) of thoracic rib.

(d) ***Parapophyses.*** Each projects laterally from centrum and articulates with ventral head (capitulum) of rib.

(e) ***Basapophyses.*** These project ventrolaterally from centrum or haemal arch, or meet ventrally to form haemal arch.

(f) ***Pleurapophyses.*** These are lateral transverse processes fused with short ribs at their tips.

(g) ***Hypapophysis.*** It is a single prominent mid-ventral projection of centrum in certain vertebrae.

Types of centra and vertebrae. An intervertebral disc or intercentrum is often present between centra of successive vertebrae in embryo. This may fuse with anterior or posterior end of a centrum changing its shape to convex or flat. On the basis of the particular shape of centra, the following main types of vertebrae occur (Fig. 4) :

(a) ***Procoelous*** (*pro* = in front + *coelous* = hollow). Anterior face of centrum is concave and

posterior face convex. e.g. typical vertebrae of frog and most reptiles.

(b) Opisthocoelous (*opistho* = at the back). Centrum is concave posteriorly and convex anteriorly. e.g. cervical vertebrae of some large ungulates.

(c) Amphicoelous (*amphi* = both). Centrum is concave at both ends. e.g. vertebrae of most fishes and tailed amphibians, 8th vertebra of frog.

(d) Acoelous or amphiplatyan (*a* = absent; *platy* = flat). Centrum is flat at both ends, without a concavity or a convexity. e.g. vertebrae of mammals.

(e) Biconvex (*bi* = two). Centrum is convex at both ends. e.g., sacral or 9th vertebra of frog.

(f) Heterocoelous (*hetero* = asymmetrical). Ends of centra are shaped like a saddle. e.g. vertebrae of modern birds.

IMPORTANT QUESTIONS

» *Long Answer Type Questions*

1. Compare the skull of lizard with bird.
2. Give an account of different types of jaw suspensorium in vertebrates.
3. Describe the pectoral and pelvic girdles of frog, *Varanus*, *Gallus* and rabbit. Show how the structure of girdle is suited to the mode of life in these animals.

» *Short Answer Type Questions*

1. Give a brief account of the following — (i) Basic structure of vertebra, (ii) Jaw suspensorium, (iii) Development of chondrocranium.

» *Multiple Choice Questions*

1. In living amphibians exoskeleton is :
   (a) Hairy (b) Horny
   (c) Nails (d) Absent
2. Which of the following is a pelvic bone?
   (a) Ilium (b) Scapula
   (c) Clavicle (d) Coracoid
3. Cartilage bone :
   (a) Parietal (b) Lacrimal
   (c) Quadrate (d) Prefrontal
4. Cranium is a constituent of :
   (a) Dermatocranium (b) Splanchocranium
   (c) Visceral skeleton (d) Neurocranium
5. Pituitary gland is housed in :
   (a) Hypophyseal fenestra (b) Olfactory capsule
   (c) Ethmoid plate
   (d) Basal plate
6. Skull in cyclostomes is made of :
   (a) Replacing bones (b) Cartilage
   (c) Membrane bones (d) Dermal plate
7. In modern amphibians the collumella of middle ear is modified :
   (a) Basisphenoid (b) Sphenoid
   (c) Hyomandibular (d) Mandibular
8. Foramen magnum in birds faces :
   (a) Upwards (b) Downwards
   (c) Left (d) Right
9. The jaw suspensorium in elasmobranchs :
   (a) Autodiastylic (b) Amphistylic
   (c) Autostylic (d) Hyostylic
10. A single prominent mid-ventral of centrum in vertebrates :
    (a) Hypapophysis (b) Zygapophysis
    (c) Diapophysis (d) Parapophysis

ANSWERS

1. (d) 2. (a) 3. (c) 4. (d) 5. (a) 6. (b) 7. (c) 8. (b) 9. (d) 10. (a).

53

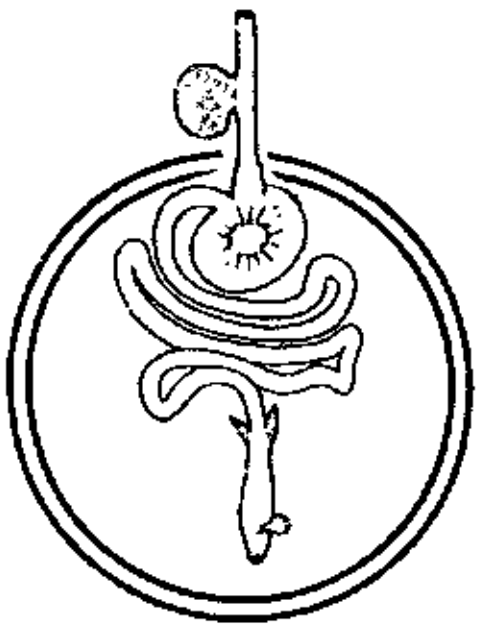

Digestive System in Vertebrates

Oxygen, water and food are necessary for the continuance of life. O_2 enters the body through the agency of respiratory system, but water and food are first taken into the *digestive tract* of every living being. Associated with the tract are its *derivatives* or *accessory organs*, such as tongue, teeth, oral glands, pancreas, liver, gall bladder, etc. The digestive tract and associated accessory organs together constitute the *digestive system*. The basic pattern of digestive system is similar in all vertebrates.

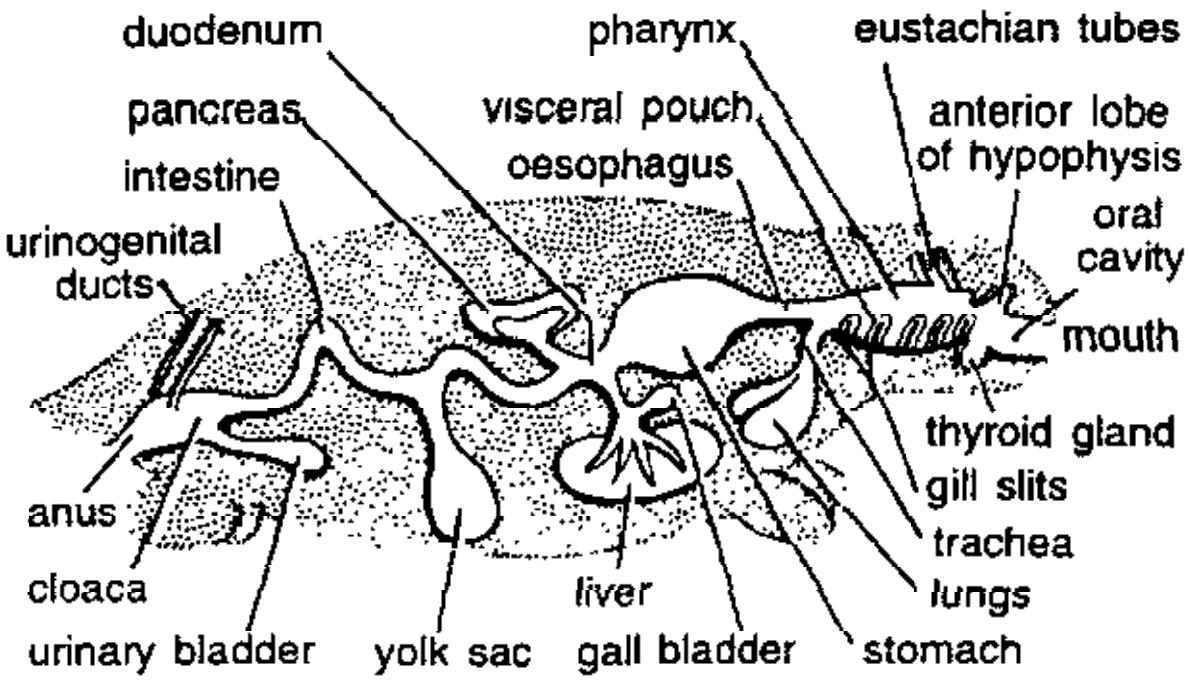

Fig. 1. Alimentary canal and its chief derivatives in a vertebrate.

Embryonic Digestive Tract

Archenteron. The digestive system is one of the earliest to form during embryonic development of vertebrates. The embryonic digestive tract or alimentary canal is endodermal in origin and termed the *primitive gut*, *archenteron* or *mesenteron* (Fig. 1). Its part containing yolk or connected by a narrow stalk with yolk sac is called *midgut*. The part anterior to midgut is *foregut* and posterior to it is *hindgut*. Foregut differentiates into oral cavity, pharynx, oesophagus, stomach and most of the small intestine of the adult. Hindgut forms the large intestine and cloaca. Only the linings of these organs are endodermal, while connective tissue and muscles in their walls are derived from mesoderm.

A midventral invagination of ectoderm of head, called *stomodaeum*, opens into oral cavity.

Thus, anterior portion of oral cavity is ectodermal, while its posterior portion is endodermal. A similar ectodermal midventral caudal invagination, called *proctodaeum*, leads into hindgut. It gives rise to the terminal ectodermal part of cloaca in lower vertebrates, and to rectum in mammals. Ectoderm of oral cavity gives rise to enamel of teeth, epithelial covering of tongue and anterior part of oral cavity, several types of oral glands (poison, salivary, mucous, etc.), and to Rathke's pouch forming adenohypophysis.

Mesenteries. Embryonic gut from stomach to cloaca is attached to mid-dorsal body wall by a continuous double fold of peritoneum, the *dorsal mesentery*, and to mid-ventral bodywall by a *ventral mesentery*. Much of dorsal mesentery persists throughout life, but most of ventral mesentery disappears except near liver and urinary bladder. Nerves and blood vessels connect to the organs through mesenteries.

Cilia. Cilia often occur in the digestive tract of vertebrates. It is entirely ciliated in adult *Branchiostoma* and in many larval vertebrates commencing with ammocoetes. Cilia are retained in the oral cavity, pharynx, oesophagus and stomach of amphibians, in stomach of many teleosts, in caeca of some birds and in many other parts in various species. They occur temporarily in stomach of human foetus.

Alimentary Canal

The term *alimentary canal* or *digestive tract* in vertebrates refers to an internal tube, seldom straight and often tortuously coiled, running from an anterior mouth opening in head to a posterior anal or cloacal aperture at the base of tail. It is designed for ingestion, digestion and absorption of food stuffs and egestion of undigested wastes. Major parts of alimentary canal are : oral cavity, pharynx, oesophagus, stomach, and small and large intestines (Figs. 2 & 4). Chief accessory organs associated with the alimentary canal are : tongue, teeth, oral glands, pancreas, liver, gall bladder, etc. Various modifications of alimentary canal in different vertebrates include : (i) lengthening of various parts by looping or coiling, (ii) formation of diverticula or enlargements (e.g. crop, caecum, stomach compartments), and (iii) development of internal folds (e.g. spiral valve, villi, typhlosole, papillae, rugae, etc).

Histology. Wall of alimentary canal of vertebrates is made of 4 distinct concentric layers or coats. (i) The outermost *serosa* or *serous coat* is *visceral peritoneum*, made by mesothelial cells and a thin layer of connective tissue. (ii) Beneath serosa, the *muscular coat* is composed of smooth muscle fibres arranged in outer *longitudinal* and inner *circular muscle fibres*, with a network of autonomic ganglionated myenteric plexus of Auerbeach between them. (iii) Beneath muscular coat lies *submucosa*, a connective tissue layer containing elastic fibres, nerves, blood and lymphatic vessels, and glands. (iv) The innermost coat or *mucosa* is further differentiated into : (a) innermost layer of *columnar epithelium*, often glandular and ciliated, supported by a thin basement membrane, (b) middle thin connective tissue, called *lamina propria* or *corium*, having blood capillaries, lacteals and nerves, and (c) outer narrow band of inner circular and outer longitudinal muscle fibres, called *muscularis mucosa*, which separates mucosa from submucosa.

[I] Mouth

Mouth is the anterior opening leading into oral cavity and is subject to a great deal of variations. In amphioxus, true mouth (enterostome) is located at the end of vestibule, perforating the membranous velum. In cyclostomes (lamprey), it is a circular opening (*cyklos* = circular + *stoma* = mouth) at the vortex of the buccal funnel, and permanently open in the absence of jaws or other mechanisms for closing it. In gnathostomes, mouth is usually terminal, although in elasmobranches and sturgeons it is located ventrally. True fleshy and muscular *lips* occur only in mammals. Muscular lips and cheeks are adaptations for sucking. In fishes, amphibians and most reptiles, mouth is surrounded by unmodified or heavily cornified skin forming immovable lips.

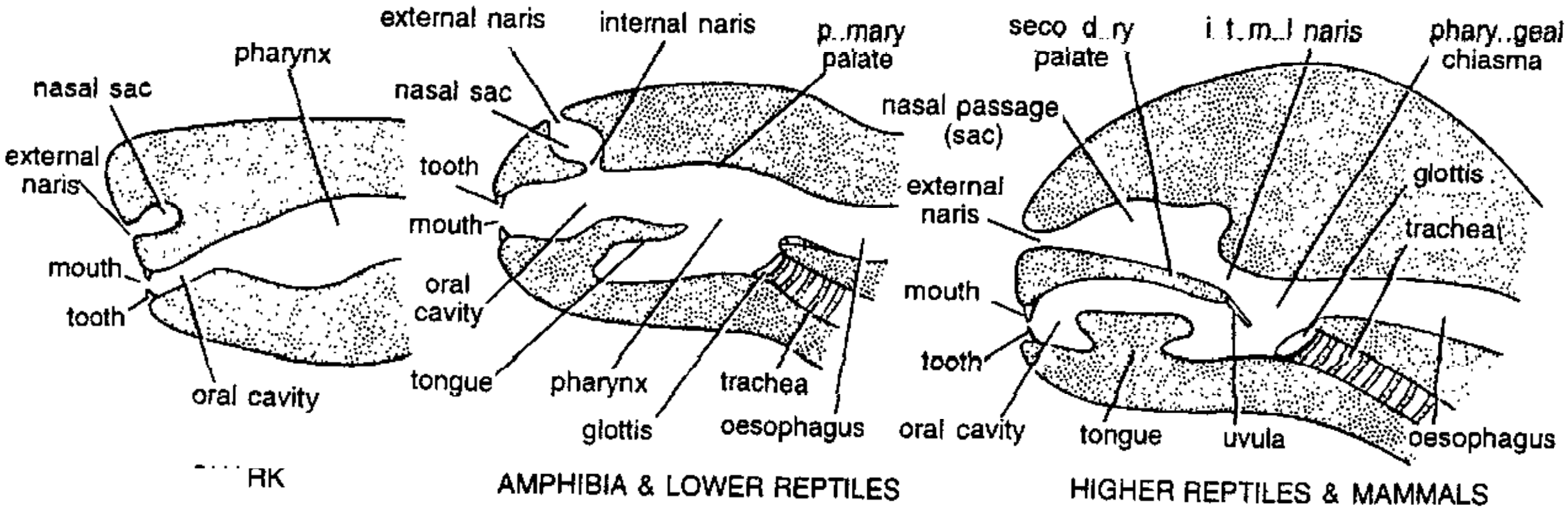

AMPHIBIA & LOWER REPTILES

HIGHER REPTILES & MAMMALS

Fig. 2. Diagrams illustrating the relation of nasal passages to oral cavities in different vertebrates.

[II] Oral cavity

In a broader sense, the term "mouth" is used as a synonym for oral cavity. In fact, oral cavity begins at the mouth and merges with pharynx without a definite line of demarcation (Fig. 2). In gnathostome fishes, oral cavity is shallow, loosely organized and roofed with dermal bones usually bearing teeth. In addition to serving as a passageway for food, it is also a passageway for water and serves for aquatic respiration. In amphibians and reptiles, oral cavity is more compact and its muscular floor serves for swallowing food and also used in breathing in the absence of a diaphragm. It reaches culmination in mammals with a space, called *vestibule*, between lips and teeth, and bounded laterally by *muscular cheeks*, thus forming an efficient sucking and chewing organ.

Nasal sacs in vertebrate embryos originate as ectodermal invaginations of head. In most fishes, nasal cavities are quite independent of oral cavity. In Dipnoi, amphibians and most reptiles, having only primitive or *primary palate*, nasal cavities open into oral cavity, rather anteriorly, by a pair of *internal nares* or *choanae*. In amniotes, with formation of a *hard* or *secondary palate*, the respiratory nasal passage becomes effectively separated from oral cavity or food passage, and the internal nares open far posteriorly into pharynx. In birds this palate is cleft so that nasal and oral cavities are in direct communication. In mammals, bony plate is continued posteriorly as a membranous *soft palate*. Sometimes, a fleshy pendulant process, the *uvula*, hangs from soft palate into laryngeal pharynx.

[III] Derivatives or accessory organs of oral cavity

These are mainly teeth, tongue, oral glands and anterior and middle lobes of pituitary (adenohypophysis).

1. Teeth. Teeth are hard and pointed structures attached to jaw bones, that aid in food-getting. Two types of teeth occur in vertebrates : epidermal and true teeth. *Epidermal teeth* are horny projections of stratum corneum and best represented in cyclostomes (lampreys). Other examples are conical projections from lips of tadpoles of some species of frogs, serrations on beaks of some turtles and birds, horny plates in duckbill, sirenians and baleen whales, and egg-tooth for cracking egg-shell before hatching in turtles, *Sphenodon*, crocodiles, birds and monotremes.

True teeth occur in all vertebrates except agnathans, sturgeons, some toads, sirens, turtles, modern birds, etc. Teeth are polyphyodont, acrodont and homodont in fish, amphibians and most reptiles, but they are diphyodont, thecodont and heterodont in mammals. Teeth are similar in structure to the placoid scales of sharks, composed of a core of dentine surmounted by a crown of

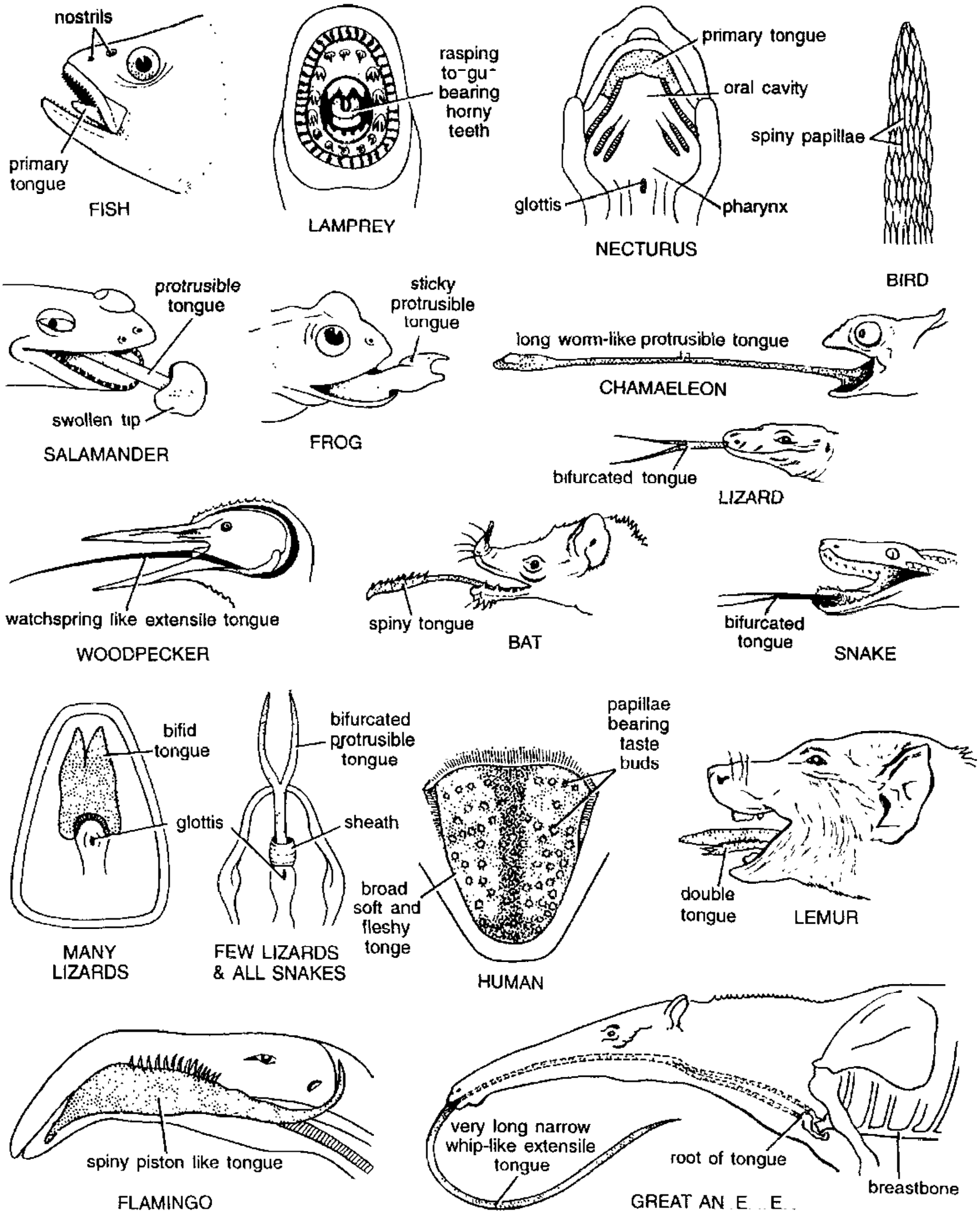

Fig. 3. Types of tongues in some vertebrates.

enamel, and are believed to have evolved from bony scales. Readers may refer to further details under the heading 'Dentition in Mammals' discussed in Chapter 34.

2. Tongue. A structure called tongue is found in the mouths of nearly all vertebrates (Fig. 3). They show much diversity and not all are homologous with the mammalian organ with which we are most familiar. In cyclostomes (lamprey), it is a thick, fleshy, extensile, rasping organ on buccal floor, armed with horny teeth. The *primary tongue* of fishes and *Necturus* is an immobile, non-muscular, sensory elevation on buccal floor, bearing teeth in some teleosts. Tongue of most amphibians (frogs, toads, salamanders) is sticky, attached at the anterior end and free at the posterior end. It can be thrust out of mouth suddenly by rapid injection of lymph, for capturing insect prey called *definite tongue.* In turtles, crocodilians, some birds and whales, tongue is immobile. In snakes, some lizards, some birds and some mammals (anteaters), it is long, highly protractile and often used for food-capture. In some lizards and snakes, it is forked at the free end, and retractile into a basal sheath. In most mammals (man), tongue is attached to buccal floor by a ligament, the frenulum. Principal role of mammalian tongue is to help in manipulation and swallowing of food. It also bears numerous microscopic taste buds. Human tongue is also of great importance in speech. In amniotes tongue is made by fusion of four parts viz., *primary tongue,* a muscular and glandular part called *tuberculum impar* and two *lingual folds.*

3. Oral glands. Vertebrates exhibit a great variety of glands opening into mouth cavity, and often named according to their location, viz palatine, lingual, sublingual, maxillary, labial, parotid, etc. As a rule, oral glands are absent or few in aquatic forms, but gradually increase in number and complexity in terrestrial forms. Fish and aquatic amphibians have only simple *mucous glands*. Poisonous snakes have large *poison glands.* The largest oral glands are enzyme-secreting *salivary glands* of mammals secretes enzyme called *salivary amylase* or *ptyalin.*

4. Adenohypophysis. Pituitary, the most important endocrine gland of vertebrates, consists of three lobes having dual embryonic origin. A ventral evagination of diencephalons, called *infundibulum,* forms the posterior lobe termed *pars nervosa* or *neurohypophysis.* Whereas a dorsal diverticulum of stomodaeum, called *Rathke's pocket,* constricts off to form the anterior and middle lobes of pituitary or *adenohypophysis.*

[IV] Pharynx

Region of foregut between oral cavity and oesophagus is termed *pharynx* which is lined by endoderm. Being concerned with digestion as well as respiration, it shows greater modifications than other parts of digestive tract. In fishes, pharynx is extensive and perforated by gill slits for aquatic respiration. In tetrapods, it is short and a crossroad between respiratory and food passages. From the wall of pharynx in embryo are derived spiracle, gill clefts, lungs, air bladder, tonsils and endocrine glands such as thymus, thyroid and parathyroids.

[V] Oesophagus

Oesophagus is a simple, muscular, distensible tube connecting pharynx with stomach. Its length is related to the length of neck. It is very short in neckless vertebrates (fishes and amphibians) but longer in amniotes, reaching extreme in birds, giraffe, etc. It may be lined internally with finger-like fleshy papillae (elasmobranchs), horny papillae (marine turtles) or longitudinal folds. In grain feeding birds (pigeon), oesophagus forms a paired or unpaired membranous sac, or *crop,* modified for storage of food. In pigeons of both sexes, epithelial lining of crop undergoes fatty degeneration controlled by a pituitary hormone, *prolactin,* forming 'pigeon's milk' which is fed to nestlings. Oesophagus has no serous coat as it lies outside coelom. In mammals when it passes diaphragm it has serous lining. Food bolus passes down oesophagus into stomach by a muscular wave of contraction and relaxation called *peristalsis.* Oesophagus exhibit difference from rest part of the alimentary canal. The important differences are — it has no visceral peritoneum

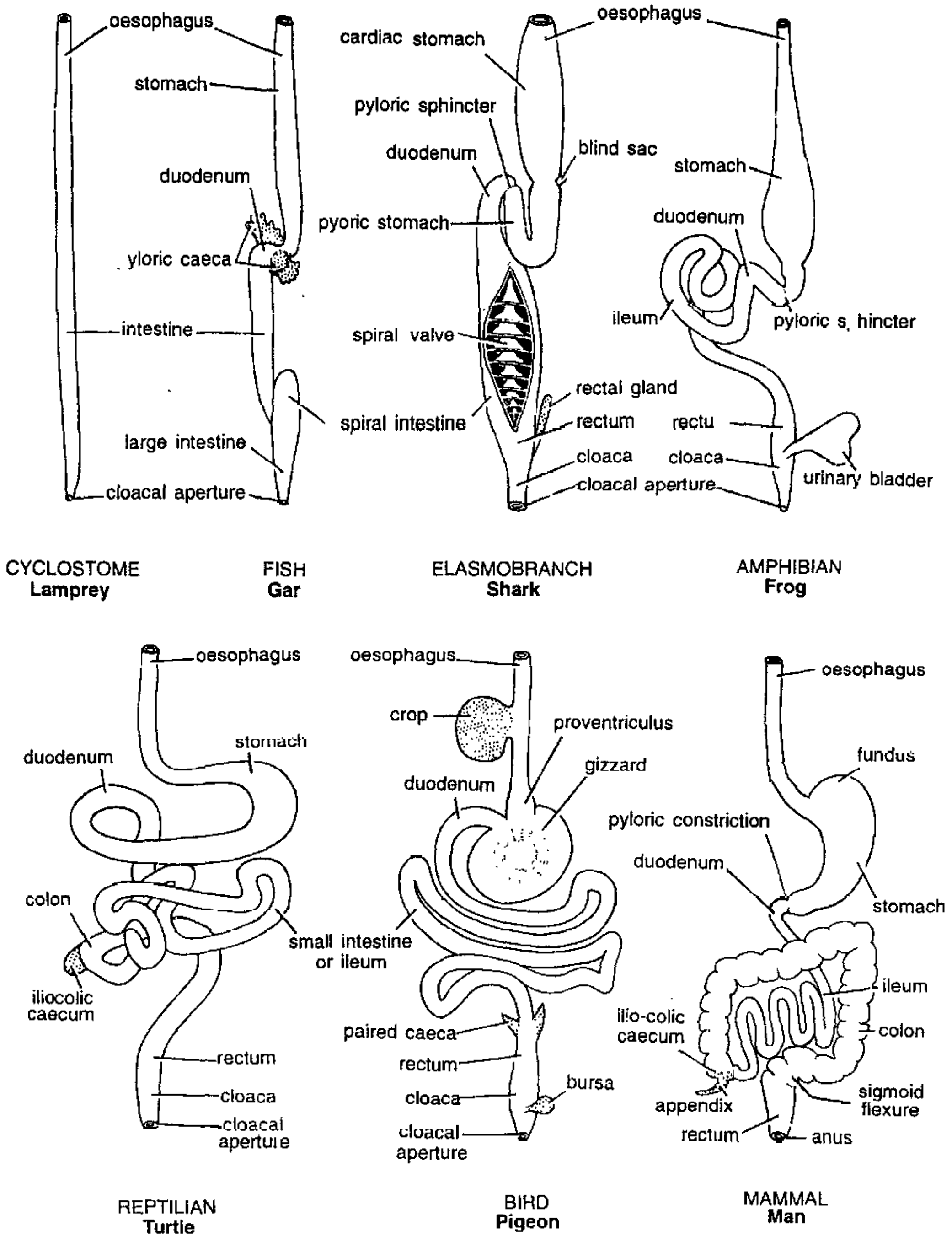

Fig. 4. Digestive tracts of some vertebrates.

lining but outer covering is *tunica adventitia.* Muscle fibers of the anterior part of the oesophagus are striped, middle part is both striped and non striped and posterior part is only unstriped muscles. But ruminants all along their oesophagus have striped and voluntary muscles. Internal mucosal lining is of stratified squamous epithelial cells.

[VI] Stomach

The sac-like muscular enlargement of digestive tract between oesophagus and intestine is called *stomach* (Fig. 5). It is held in place by *mesogaster,* a part of dorsal mesentery. It serves for temporary storage and maceration of solid food and for preliminary stages of digestion.

A *true stomach* is not present in protochordates, cyclostomes, chimaeras, lung fishes and some primitive teleosts. Only when its epithelial lining contains gastric glands, is it properly called a true stomach. Absence of stomach is considered to be an ancestral trait. A well-developed stomach occurs in elasmobranchs and tetrapods. The anterior end of stomach connecting to oesophagus is nearer heart and therefore called *cardiac end.* Main sac-like portion is termed *body.* The caudal end connected to intestine is called *pyloric end.* It terminates at a pyloric valve or sphincter called *pylorus.* In many vertebrates, especially fishes, one to several hundred finger-like *pyloric caeca* may be present at the junction of pylorus with duodenum.

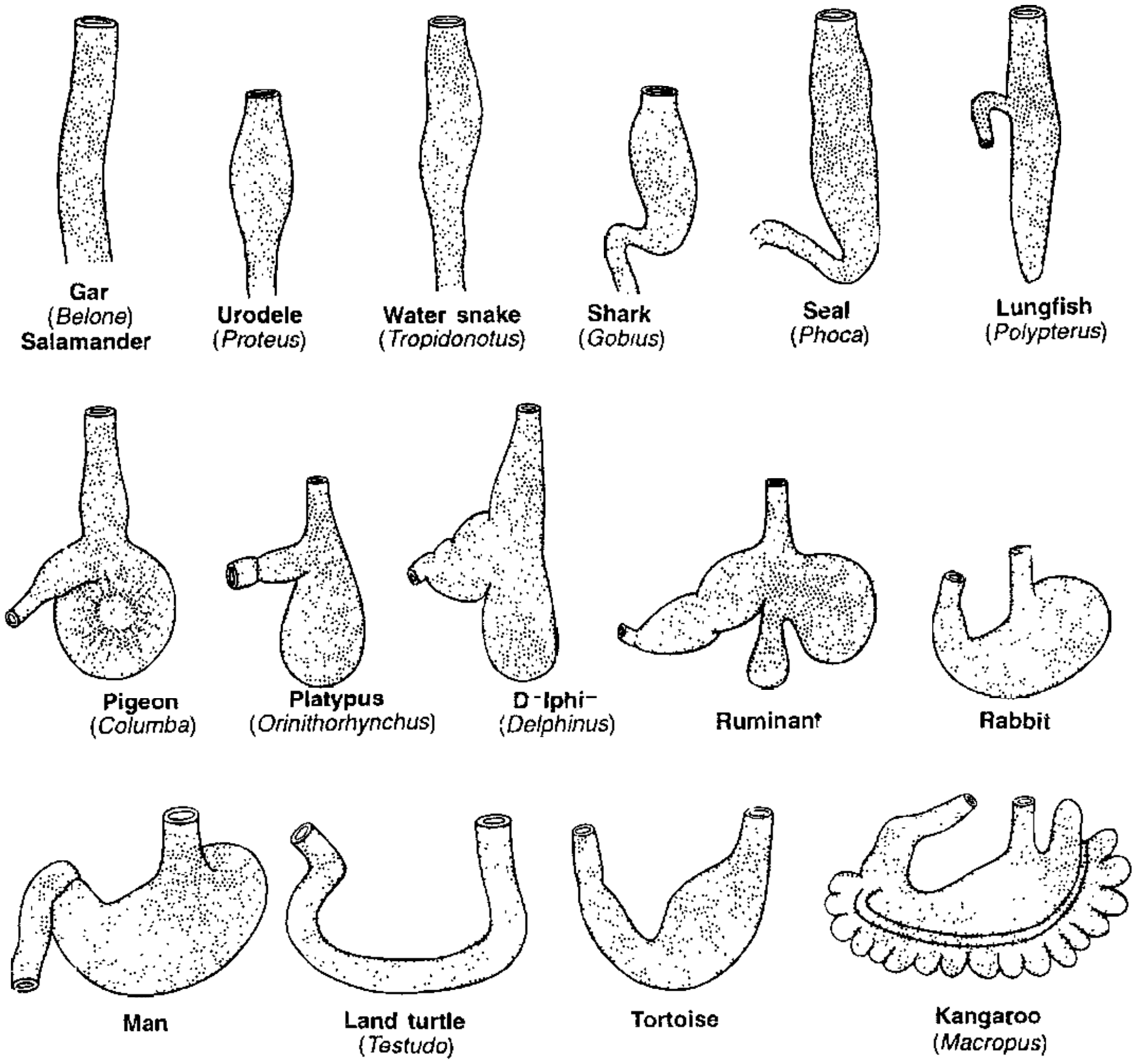

Fig 5. Different shapes of vertebrate stomachs including human.

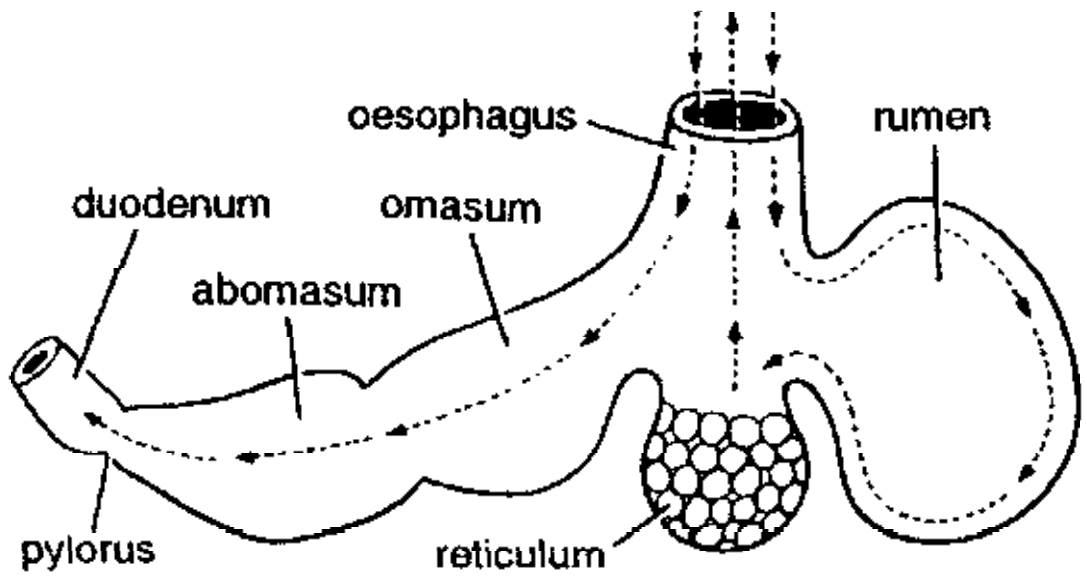

Fig. 6. Stomach of a ruminant or cud-chewing mammal. Arrows indicate course of food.

Stomach is *straight* in vertebrate embryos and may remain so throughout life in lower vertebrates (cyclostomes, gar, *Belone*, salamander, etc.). It is long and *spindle-shaped* in *Proteus*, *Necturus*, snakes and many lizards with elongated and narrow bodies. It forms a wide *curved* tube in turtles and tortoises. More often, flexures develop producing a *J-shaped* or *U-shaped* stomach (elasmobranchs, *Gobius*, seal, man etc.). As a result, stomach exhibits a short concave border, called *lesser curvature*, and a large convex border, called *greater curvature*. Expansion of greater curvature forms the so-called *fundus* region. In *Polypterus*, stomach appears like a *blind pouch* due to fusion of cardiac and pyloric limbs along lesser curvature. In crocodiles and seed-eating birds, stomach is divisible into an anterior, thin-walled *proventriculus* with gastric glands, followed by a thick-walled highly muscular *gizzard* or *ventriculus*. The latter has a tough, horny lining and contains small stone pieces or pebbles called *gastrolith* which help in maceration of food.

Stomach of mammals shows greatest modifications. It may be a simple sac or divided into *cardiac*, *fundic* and *pyloric* regions, each region with its characteristic gastric glands. In cud-chewing mammals or ruminants (cow), stomach has 4 well-defined chambers or compartments (Fig. 6). Of these, the first three chambers (*rumen*, *reticulum*, *omasum*) are claimed to be the modifications of oesophagus and serve as reservoirs of food. Only the last chamber (*abomasum* or *rennet*) represents true stomach containing gastric glands, comprising of the usual parts— cardiac, funduc and pyloric. In camel, omasum is absent and the pouch-like *water cells* projecting from rumen and reticulum probably help in digestion but do not serve for storage of water as generally believed. A pyloric enlargement in blood sucking bats serves to store blood. A true stomach is wanting in monotremes, it is represented by a wide sac devoid of glands internally and is lined throughout by stratified epithelium.

Histological stomach shows two peculiarities. The *muscularis mucosa* consists of an outer longitudinal layer and inner circular muscle layer. Epithelial lining of stomach is thick and provided with several types of glandular cells forming *gastric glands*. Gastric glands are of three types *Cardiac, fundic* and *pyloric glands.* Cardiac and fundic glands secrete mucus only but fundic glands have three types of cells— *mucus neck cells* producing mucous, *oxyntic cells* producing HCl and *Zymogen cells* producing pepsin.

[VII] Small intestine

The part of digestive tract following stomach is *intestine*, in which digestion and absorption of food take place. Hence it is the most important part of digestive tract and undergoes several modifications in vertebrates. In cyclostomes (lamprey), elasmobranchs (dogfish), some primitive bony fishes (sturgeon, *Polyodon*) and an occasional teleost, intestine is a short, straight and wide tube. Its lumen cantains a *typhlosole* or *spiral valve* which compensates for the short absorptive area. This *valvular* or *spiral intestine* is equivalent to the small intestine of higher vertebrates. Teleost and tetrapod intestine is without a spiral valve, greatly elongated, coiled and further differentiated into an anterior *small intestine* and a posterior *large intestine*. Small intestine is the chief site of digestion and absorption. Its internal surface bears numerous, small finger-like projection or *villi* which increase the absorptive area. Many bony fishes have one to several pyloric caeca, arising from small intestine. A large number of digestive glands are also present in small intestine, they are tubular called *crypts of Lieberkuhn* found all along the length of intestine and secrete mucus and group of enzymes called *saccus entericus*.

First part of small intestine is known as *duodenum*. It is short, starts at the pyloric valve and terminates beyond the entrance of ducts from pancreas and liver into it. It has characteristic *Brunner's glands* in submucosa and also secretes hormones (*secretin, cholecystokinin*) for stimulating pancreas and gall bladder to release their juices.

Duodenum is followed by remaining small intestine, called *ileum*, which is narrow, greatly elongated, and much coiled. Only in mammals, small intestine beyond duodenum is divided into an anterior two-fifth *jejunum* and a posterior three-fifth *ileum*. Nodules of lymphoid tissues called *Peyer's patches* are found in ileum. However, the division is somewhat arbitrary and based on differences in shape of their villi and in nature of their glands and walls.

[VIII] Large intestine

Large intestine of most fishes and amphibians (*colon* or *rectum*) is wider than small intestine. It is straight, short and leads into a posterior terminal chamber, the *cloaca*. Cloaca also receives the urinary and genital ducts and opens to outside through a *cloacal aperture*. In reptiles, birds and mammals, large intestine is longer and divided into a proximal *colon* and a distal *rectum*, the latter ending into cloaca. All mammals except the monotremes and many bony fishes, lack a cloaca. Their rectum opens directly to outside through *anus*, while the urinary and genital ducts also open independently. Rectum of mammals is derived by partitioning of embryonic cloaca and, therefore, it is not homologous with the rectum of other vertebrates.

In tetrapods, and *ileocaecal valve* or *ileocolic sphincter* is present at the junction of small and large intestines, but absent in fishes. It prevents bacteria in colon from entering ileum. In amniotes, at the ileocolic junction is found an *ileocolic caecum*, usually two in birds. This contains cellulose-digesting bacteria and is very long, even coiled, in such herbivorous mammals as rabbit or horse feeding heavily on cellulose. Man, monkeys and apes have a small caecum, bearing a vestigial *vermiform appendix*. The *rectal gland* of elasmobranchs is a caecum that secretes sodium chloride. *Bursa fabricii* is a blind pouch of lymphatic tissue arising from dorsal wall of proctodaeum in young birds, but atrophies in the adults.

Digestive Glands

1. Liver. Liver occurs in all vertebrates and is the largest gland of the body. It arises as a single or double ventral diverticulum from the floor of embryonic duodenum. This liver bud or rudiment, soon divides into anterior and posterior parts. Anterior part branches repeatedly to become the *liver proper* of the adult animal (Fig. 7). Posterior part forms the *gall bladder*, *cystic duct* and *common bile duct* receiving numerous *hepatic ducts* from the liver proper and emptying into duodenum. Shape and division into lobes of adult liver varies in different vertebrates. Colour is also variable, especially in teleosts, where it may be green, yellow, orange, brown or red.

A true liver is absent in protochordates. *Hepatic caecum* of amphioxus and *digestive glands* of ascidians have somewhat different characters. In cyclostomes, it is small and single-lobed in lampreys but two-lobed in hagfishes. Liver is elongated, narrow and cylindrical in fishes, urodeles and snakes, but short, broad and flattened in birds and mammals. It is bilobed in elasmobranchs, two or three-lobed in teleosts, amphibians, reptiles and birds, and many-lobed in mammals. Liver is relatively large in carnivores than herbivores.

Liver cells manufacture alkaline *bile* which is stored in gall bladder before getting released into duodenum. Bile contains no digestive enzymes, nevertheless it neutralizes acidity of liquid food or chyme entering intestine and aids in fat digestion and absorption. Detailed functions of liver are given in Chapter 50. No other gland of vertebrate body has more varied functions than that of liver. But, curiously enough, it has never acquired any endocrine function.

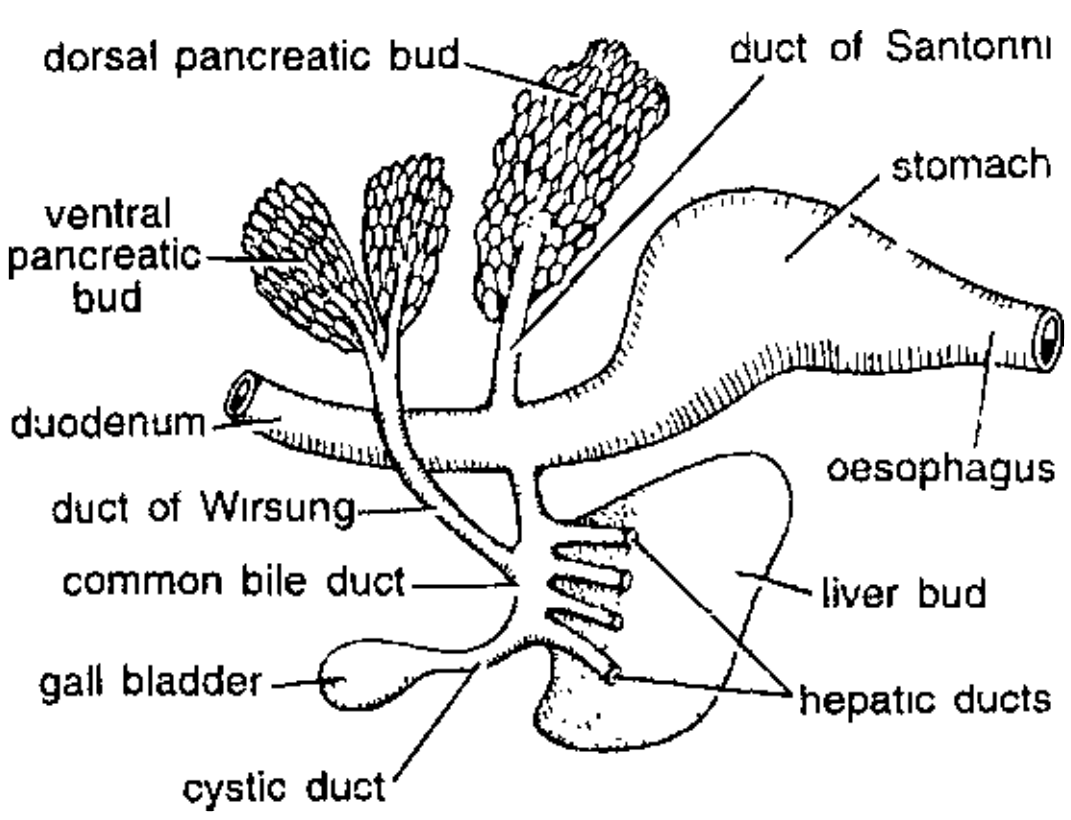

Fig. 7. Embryonic development of liver, gall bladder and pancreas.

A *gall bladder* is present in hagfishes and all higher vertebrates. However, it is absent in lampreys, many birds (pigeon) and many mammals (rats, hyrax, whales some Artiodactyla and all Perissodactyla). Gall bladder is not essential and can be removed surgically without any harm.

2. Pancreas. Pancreas is also a constant structure of all vertebrates and second largest digestive gland after liver. Typically, pancreas arises as one or two ventral diverticula from liver bud, and one dorsal diverticulum from embryonic duodenum. It is endodermal in origin from embryonic archenteron. Distal portions of diverticula divide to form acinous type glands, one *dorsal pancreas* and one *ventral pancreas*. Both may persist, as in fishes, but more generally the two unite to form a single gland as in tetrapods. Proximal portions of diverticula form *pancreatic ducts* all of which may persist. But usually the ducts undergo reduction or fusion, so that only one or two pancreatic ducts remain as in mammals. The ducts open into duodenum separately or jointly or one of them may unite with the common bile duct (Fig. 7).

Pancreas plays a dual role. It is partly *exocrine* secreting digestive enzymes through pancreatic ducts into duodenum, and partly *endocrine* secreting hormones such as *insulin*. A somewhat detailed treatment of pancreas can be seen in Chapter 50.

No pancreas is present in lancelet. In lampreys, some teleosts, lungfishes and lower tetrapods, it is distributed diffusely in liver, mesenteries and intestinal wall and probably only exocrine in function. In elasmobranchs and higher tetrapods, pancreas is well-defined and compact.

IMPORTANT QUESTIONS

» *Long Answer Type Questions*

1. Give a comparative account of digestive system of *Uromastix* and *Columba*.
2. Compare the digestive system of pigeon with rabbit and give reasons for their differences.
3. Give a comparative account of stomach in different vertebrates you have studied.
4. Give a general account of teeh.

» *Short Answer Type Questions*

1. Write notes on— (i) Colon, (ii) Gizzard, (iii) Liver, (iv) Pancreas, (v) Ruminant stomach, (vi) glands of digestive system.

» *Multiple Choice Questions*

1. The part of archenteron connected to yolk sac :
   (a) Primitive gut (b) Fore gut
   (c) Mid gut (d) Hind gut
2. Oesophagus in adult vertebrates is derived from :
   (a) Primitive gut (b) Fore gut
   (c) Mid gut (d) Hind gut
3. True muscular lips are found in :
   (a) Cyclostomes (b) Fishes
   (c) Amphibians (d) Mammals
4. In frogs tongue is :
   (a) Primary tongue (b) Definite tongue
   (c) Horny tongue (d) Immobile tongue
5. The largest oral glands are found in :
   (a) Mammals (b) Birds
   (c) Reptiles (d) Amphibians
6. Largest oesophagus is found in :
   (a) Dog fish (b) Frog
   (c) Giraffe (d) Sparrow
7. Epithelial lining in a true stomach contains :
   (a) Salivary glands (b) Mucous glands
   (c) Goblet cells (d) Gastric glands
8. In ruminants true stomach is represented by :
   (a) Abomasum (b) Reticulum
   (c) Rumen (d) Omasum

ANSWERS

1. (c) 2. (b) 3. (d) 4. (b) 5. (a) 6. (c) 7. (d) 8. (a)

54

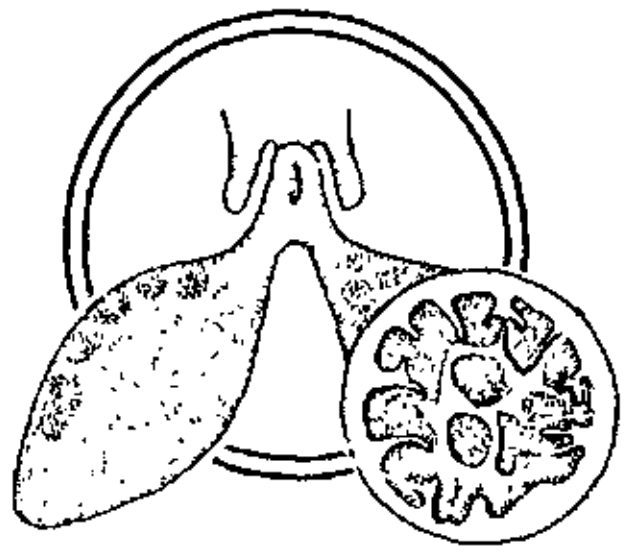

Respiratory System in Vertebrates

Every cell in a living organism consumes oxygen (O_2) during oxidation of substances resulting in the release of heat and energy and production of carbon dioxide (CO_2). This CO_2 acts as a poison for protoplasm unless removed from the body. The term *respiration* is used in several senses. According to a simple definition, it means intake of O_2 and getting rid of CO_2 by a living organism. The system designed for exchange of gases (O_2 and CO_2) between the organism and its environment is termed the *respiratory system.*

Respiratory Organs

Exchange of O_2 and CO_2 in an organism takes place in two locations. During *internal respiration,* also termed *cellular* or *tissue* respiration, gaseous exchange occurs between blood and tissues or cells of the body. During *external respiration,* gaseous exchange takes place between blood and the external environment. Blood serves as a transportation medium for carrying O_2 and CO_2 away from the body cells. The body structures which are needed for gaseous exchange between the blood and the surrounding medium are known as *respiratory organs.* Depending on the type of medium, vertebrates have two principal types of respiratory organs : *gills* for aquatic respiration (in water) and *lungs* for terrestrial respiration (in air). The same animal may have both gills as well as lungs. *Accessory respiratory organs* are also present in some vertebrates. All respiratory structures consist of a moist, semipermeable and highly vascularized membrane, exposed to the external medium, so that exchange of gases takes place by diffusion between the body blood and the environment. Gills and lungs are derivatives of the embryonic pharynx.

Gills

Gills or *branchiae* are the aquatic respiratory organs of fishes and amphibians. Amniotes do not utilize gills at any time in their embryonic or adult life. In addition to gas exchange, gills may serve for loss or gain of water, and elimination of salts in marine teleosts. On the basis of their location, gills are of two general types : *internal gills* and *external gills*. In some animals, both internal and external gills are present.

[I] Internal or true gills

Internal or true gills are characteristic of fishes. They are located in the gills slits and attached to the visceral arches. In amniotes, embryonic pharyngeal pouches do not open by gill slits to outside in the adults, so that no gills are present in them.

1. Gill slits. Gill slits are one of the most fundamental traits of the Chordata. In the embryo, the pharyngeal cavity is connected to the outside by a series of lateral openings, known as *pharyngeal clefts* or simply *gill slits*. These persist in the adult state of protochordates, cyclostomes, fishes and certain amphibians, but become reduced, abolished or modified in higher vertebrates. The number of gill slits varies in different chordates— 140 in amphioxus, 6-14 pairs in cyclostomes, 5 pairs in most elasmobranchs, 6 pairs in *Hexanchus*, 7 pairs in *Heptanchus*, 4 pairs in chimaeras, 5 pairs in most bony fishes, and 4 pairs in some teleosts. The gill slits are separated from one another by partitions called *visceral* or *gill arches*. The arches are supported by skeletal structures of splanchnocranium, together forming the *visceral skeleton*.

2. Structure or a true gill. True gills are developed on the walls of some gill clefts or gill arches (Fig. 1). Typically, a gill is composed of two rows of numerous *gill filaments* or *lamellae*. These are derived from epithelium on either side of an *interbranchial septum* containing arteries and supported by the branchial cartilage or bone of a gill arch. A single row of lamellae on one side of branchial *septum* forms only half the gill, called a *demibranch* or *hemibranch*. A septum with two attached demibranchs comprise a complete gill or *holobranch*. Gill filaments are richly supplied with blood capillaries and it is here that exchange of gases with water takes place.

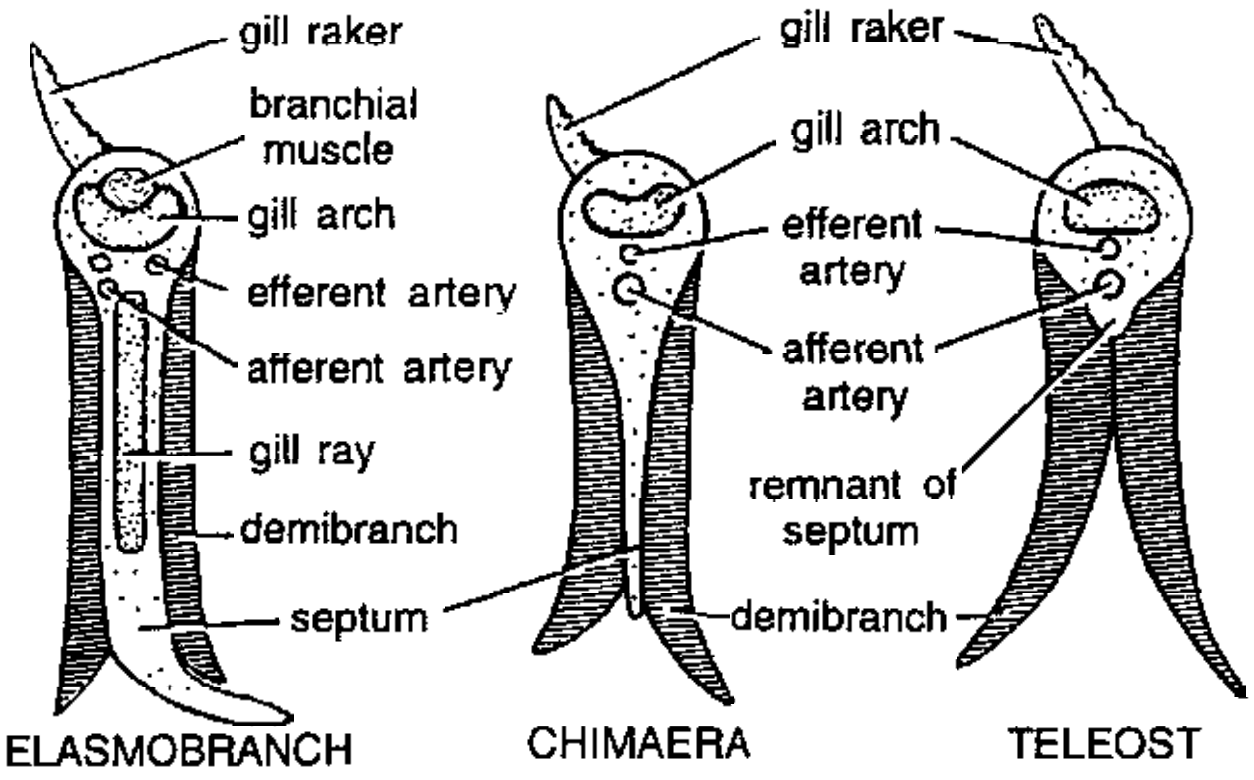

Fig. 1. Types of gills in fishes in section.

Gills of elasmobranchs (e.g. dogfish) are generalized in structure and relationships. Gills of bony fishes are also basically similar but show the following differences :

(a) Operculum. In a bony fish, a bony flap, called *operculum* or *gill cover*, arises from the hyoid arch and covers the gills in a common *opercular cavity* which opens by a single slit-like crescentic *external gill opening* behind.

(b) Interbranchial septum. The median septum is best developed in elasmobranchs. It is reduced in some intermediate fishes like chimaeras. It is greatly reduced or virtually absent in teleosts.

(c) Spiracles. In elasmobranchs and ganoids, the first gill slit, between mandibular and hyoid arches, bears a reduced *pseudobranch* and opens to outside through a small opening, the *spiracle*. In chimaeras, lung fishes and teleosts, spiracles become either closed or lost in the adult.

(d) Reduction in number of demibranchs. Number of gills greatly varies among fishes. There are 7 pairs in *Heptanchus*, 6 pairs in *Hexanchus* and 5 pairs in most elasmobranchs in addition to spiracle. However, the demibranch found on hyoid arch in elasmobranchs is lost in modern ganoids and teleosts which have only 4 holobranchs. Additional demibranchs are lost in some lungfishes. The extreme case of reduction is found in the eel *Amphipnous* in which first and fourth branchial arches are without gills, while the second arch retains only a demibranch.

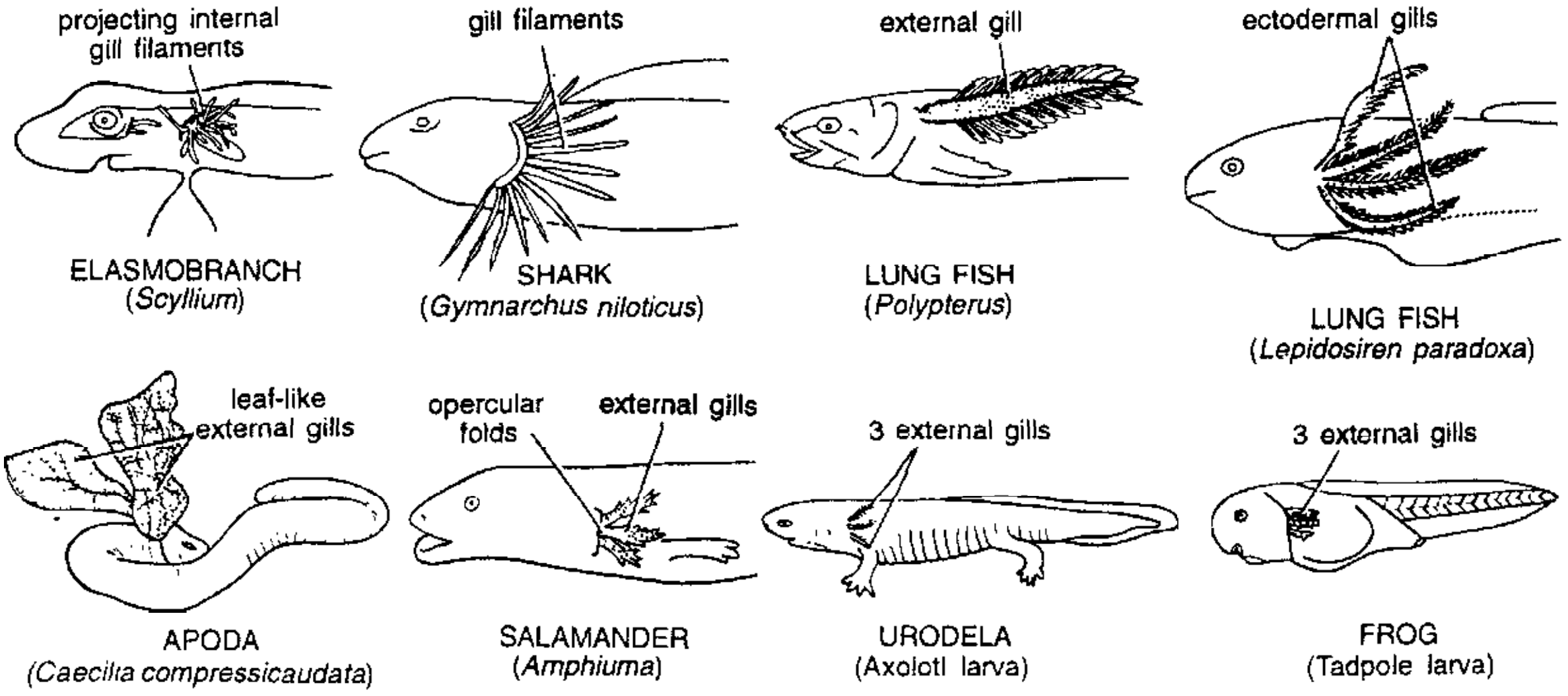

Fig. 2 Larval external gills of fishes and amphibians.

[II] External or larval gills

As against true gills, the external gills are formed as branching outgrowths from the exposed outer epithelium of gill arches and not from that of the pharyngeal pouches (Fig. 2). They are ectodermal in origin, and usually temporary organs found only in larval stages, hence also termed *larval gills.* They occur in the larvae of lampreys, a few bony fishes including *Polypterus* (bichir), lungfishes (e.g. *Lepidosiren*), and all amphibians including caecilians. In amphibians, larval external gills are absorbed at the time of metamorphosis, but in water-living perennibranchiate urodeles, both external gills and gill slits persist during adult life. In *Amphiuma,* gills are absorbed but gill slits remain. Gills assume various shapes being pectinate, bipinnate, dendritic, leaf-like, etc. Each gill consists of a narrow main central axis bearing a double row of filaments. Thoroughly vascularized by aortic arches, external gills are simply waved in water, and no respiratory water current passes through gill slits as in the case of true gills.

Lungs and Ducts

Lungs are the essential respiratory organs of land vertebrates or tetrapods and lung fishes. They are very elastic and distensible. Phylogenetic history of the development of lung is still obscure. Most accepted theory regarding the origin of lung was forwarded by Goethe. He believes that they are derived from the last pair of gill pouches which do not open to exterior through gill slits. Lungs receive blood supply from 6th aortic arch also strongly supports this view. In tetrapod embryos, lungs arise as a single midventral diverticulum (*lung primordium*) from the floor of pharynx (Fig. 3). It soon bifurcates into right and left *lung buds.* The undivided common portion develops into *windpipe* or *trachea* and *larynx* and opens into pharynx through *glottis.* Each lung bud branches repeatedly and grows posteriorly into coelom, invested by mesoderm. Thus, each lung has an inner endodermal lining derived form embryonic gut, an outer visceral peritoneum and in between the two a mesodermal mesenchyme containing lymph and blood vessels, nerve and smooth muscle fibres and connective tissue.

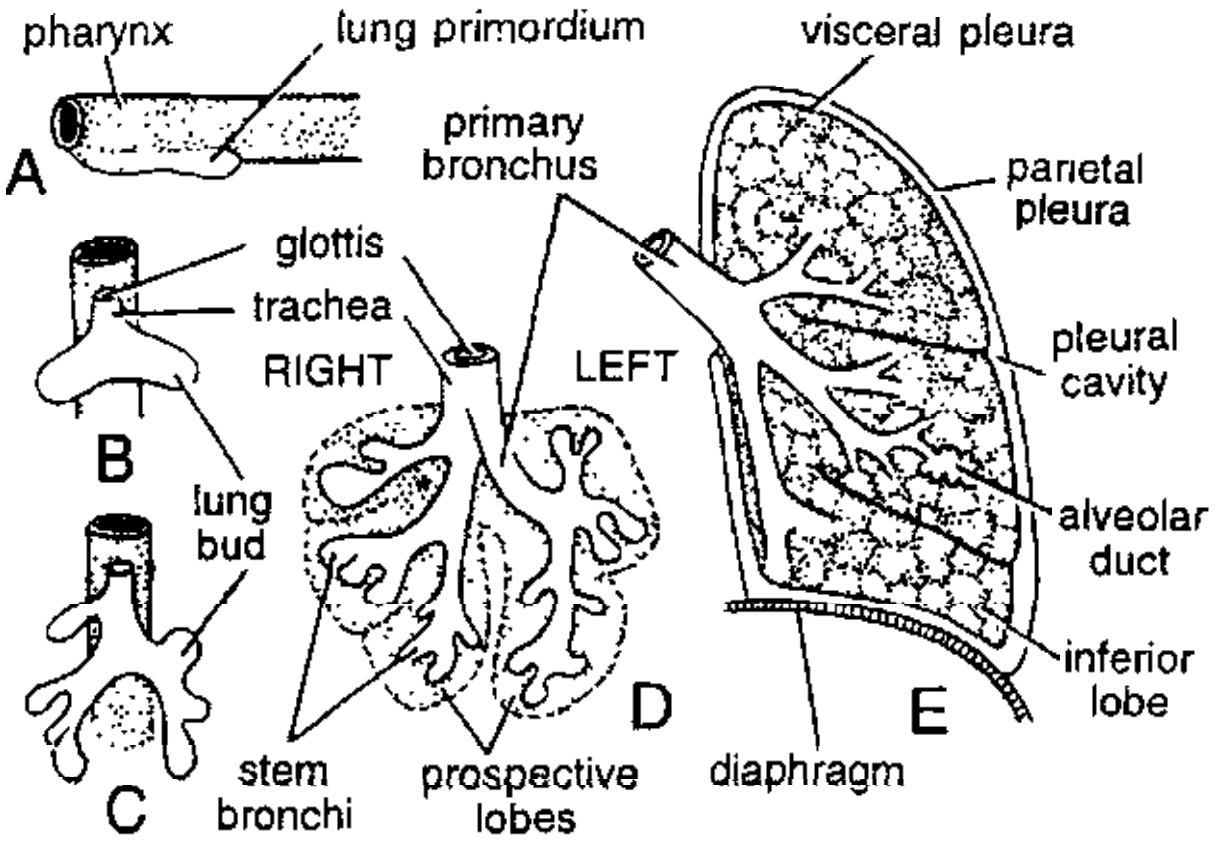

Fig. 3. Stages in development of a vertebrate lung in embryo. A—Lung primordium. B & C—Lung buds. D—Embryonic lung. E—Lung at birth.

Larynx. Beginnings of larynx are seen in Amphibia. In its simplest condition (*Necturus*), it is supported by a pair of *lateral cartilages*, bounding the slit-like glottis. In other amphibians, each lateral cartilage is divided into a dorsal *arytenoid* and a ventral *cricoid*. Sometimes both the *cricoids* fuse to form a cartilaginous ring (frog). It is suggested that these skeletal parts have evolved from the modification of vestiges of *branchial arch* (probably VI). It is further supported that this region is innervated by a branch of vagus (the X cranial nerve). In Anura, inner lining of laryngotracheal chamber forms two muscular bands, or *vocal cords*, which vibrate to produce various calls. Larynx is scarcely more developed in reptiles. *Cricoid* in case of reptiles is more differentiated than amphibians and in many cases gives off process with which *arytenoids* are movably articulated. It is small and rudimentary in birds in which another organ, the *syrinx*, located at the lower end of trachea, is responsible for sound production. In most common type of syrinx (*Bronchotracheal type*), there is tympanum formed of last tracheal cartilage. Besides this, into this box like structure certain membranes project from the walls of bronchi viz., *membrana tympaniformis interna* and *membrana tympaniformis externa*. However, in singing birds there is also another paired vibratory membrane called *membrana semilunaris* which extend dorsoventrally near the junction of bronchi and trachea. A bony ridge *pessulus* support these membranes. Larynx reaches its greatest point of evolution in mammals. Besides paired arytenoid and single cricoid, a single *thyroid cartilage* is added on ventral surface of larynx. Although, thyroid cartilage was paired initially as in monotremes it is made of two plates rather than one. Moreover, in all mammals it develops from remains of paired branchial arch embryologically. The vocal cords reach maximum differentiation in mammals. They are two pairs band like folds on the inner walls of larynx, extending between arytenoids and thyroid cartilages, one above the other. The upper is called *false* and lower one is called *true* vocal cord. Elephants do not have false vocal cord and hippopotamus has no vocal cords. A flap-like muscular *epiglottis* is present in front of glottis and is characteristic of mammals.

Trachea. Part of air duct between larynx and lungs is termed *trachea*. Its wall is prevented from collapsing due to a series of usually incomplete *cartilaginous rings* arranged in various ways. Lower end of trachea bifurcates forming two *bronchi*, lined with cilia, and each entering a lung. In Anura, trachea is extremely short or absent, merging with larynx to form a laryngo-tracheal chamber. A definite trachea is differentiated in *Siren*, *Amphiuma* and *Gymnophiona* only. It reaches to a length of 4-5 cm. The walls are further strengthened by a series of small, irregular cartilages, which are usually united to form bands. Length of trachea varies in reptiles depending upon that of the neck. The cartilage rings of trachea gradually become more solid and complete but are generally incomplete dorsally. In lizards and snakes the anterior cartilage round the trachea forms complete rings. In birds, trachea is unusually elongated, and tracheal rings are complete and ossified. In mammals, trachea is variable.

Lungs proper. Swimming bladders of lung fishes *(Protopterus)* are better lungs than those of most amphibians. Two lungs of modern Amphibia

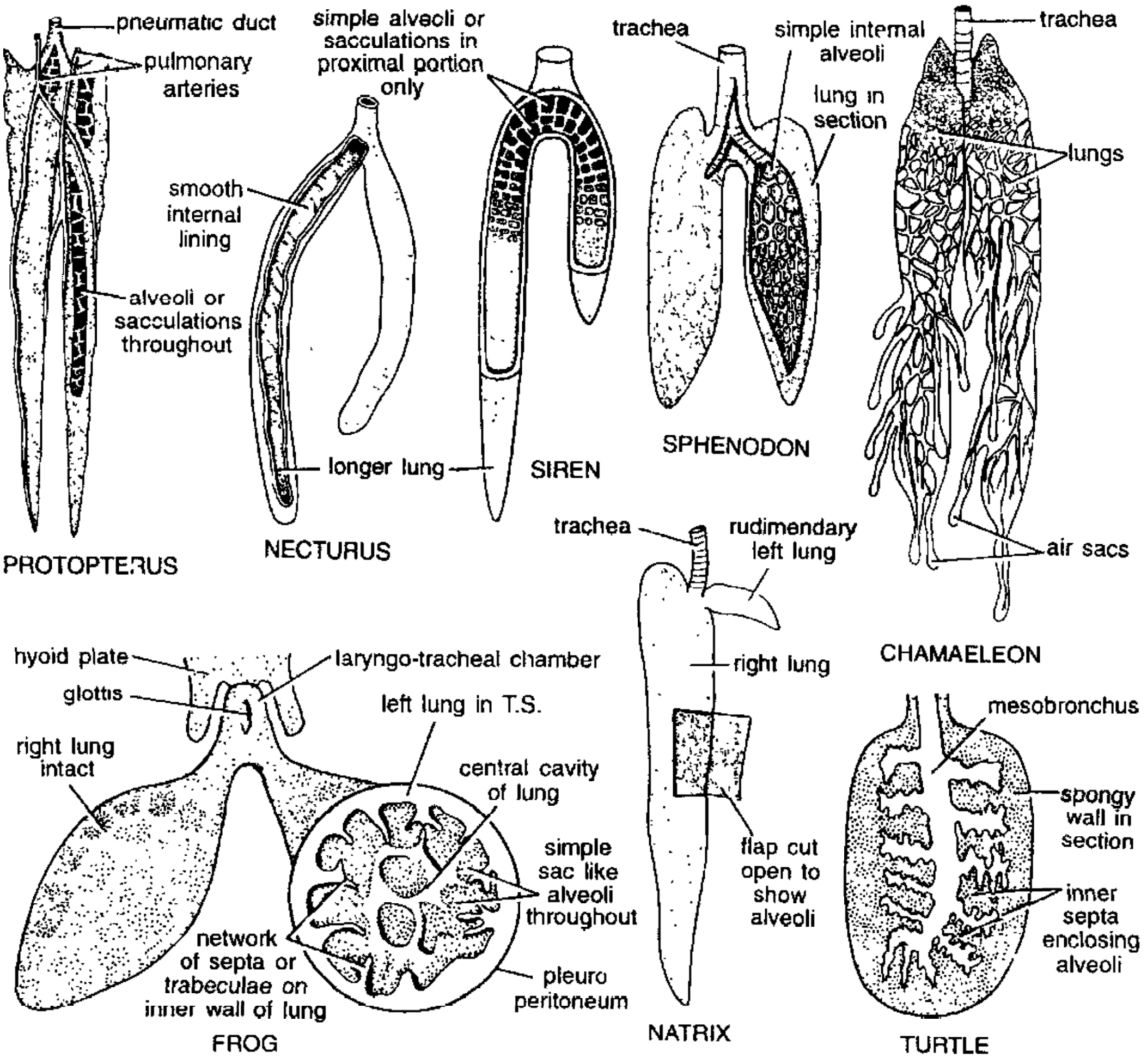

Fig. 4. Different types of vertebrate lungs.

are simple, hollow sacs with a wide central cavity, and suspended freely into peritoneal body cavity (Fig. 4). They are elongate in urodeles but bulbous in anurans. Left lung is usually longer in urodeles but rudimentary in caecilians. Internal lining of lungs may be smooth *(Necturus)*, or may have simple sacculations proximally *(Siren, Amphiuma)*. In frogs and toads (anurans), lung wall may be divided peripherally by a network of folds or *trabeculae* into *air sacs* or *alveoli*. They are richly vascular, lined with mucous epithelium and their inner edges bearing tall ciliated columnar cells.

Lungs of reptiles are more complicated and also abdominal in location. In *Sphenodon* and snakes, lungs remain simple thin-walled sacs. In legless lizards and snakes, left lung may be rudimentary or absent. In Boa and Python both the lungs are functional but left one is slightly smaller. In lizards and turtles, wall of lung is considerably thickened due to inclusion of greater amount of highly vascularized connective tissue in partitions, so that the whole lung becomes spongy. The crocodilian lung most nearly approaches the condition found in mammals. Reptilian lungs also hang freely in the body cavity. In chamaeleons, several long, thin-walled, sac-like diverticula or *air sacs* arise from distal portion of lungs. With the help of these they use to swell to some extent which frightens the predator and helps it to escape.

Structure and function of lungs in birds are not wholly understood (Fig. 5). Avian lungs are unique in architecture and greatly modified due to

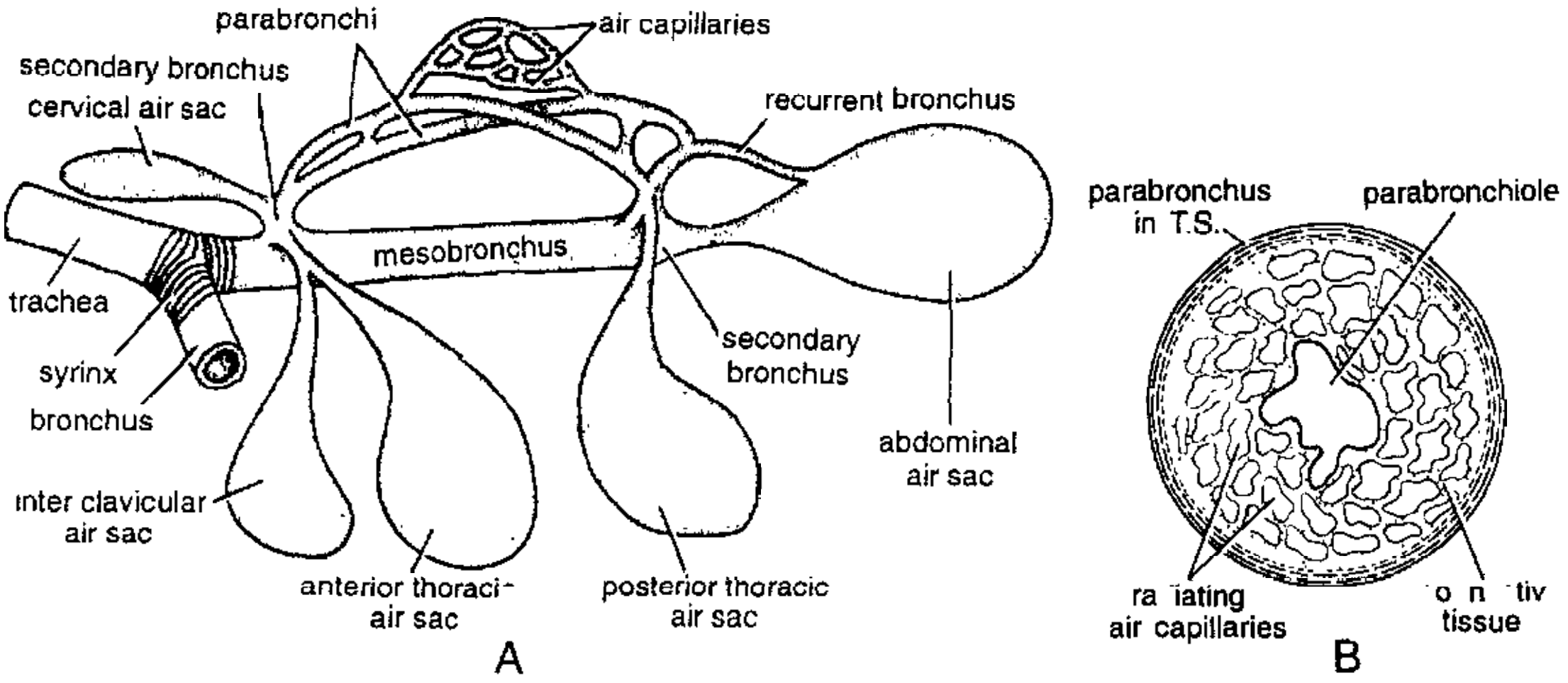

Fig 5. Avian lung. A—Scheme of architecture of a lung and air sacs in a bird. B—Section of a parabronchus showing radiating infundibular or air capillaries.

their aerial mode of life. They show many peculiarities not found in other groups. Lungs are small, compact, spongy and only slightly capable of contraction and expansion. They are placed outside coelom in pleural cavities. The lower or ventral surface of each lung is closely invested by thin fibrous membrane called *pulmonary.* Several muscle bands called, *costo-pulmonary* muscles which arise from the vertebral ribs are inserted into pleura which are supplied with *inter-costal nerves.* They give out several thin-walled membranous *air sacs* (= *Cellulae aereae*) that invade most parts of the body. The bronchus after entering the lung, divides repeatedly forming a network of anastomosing *air capillaries* which do not terminate blindly. As a result of these novelties, avian lungs become highly efficient organs.

Mammalian lungs are also highly developed, spongy and very elastic (Fig. 6). They lie protected in special chambers, called *pleural cavities,* which are separated from rest of perivisceral body cavity by a muscular *diaphragm.* The pericardium containing heart lies between the pleural cavities. In most mammals, lungs are subdivided externally into lobes, usually more on the right. Thus while there are only 2 left lobes, the right lung has 3 lobes in man and 4 lobes in rabbit. In certain mammals such as whales, sirenians, elephants, hyrax, and many perissodactyles, lungs are simple and without lobes. In monotremes and rats, only the right lung is lobulated. The mammalian lung consists like an elaborate branched respiratory tree. The bronchus divides repeatedly inside the lung ultimately resulting into a large number of terminal grape-like clusters of *air-sacs* or *alveoli.* Being terminal and blind, they always retain a certain amount of residual air after every expiration. In mammals, intercostal muscles, ribs, diaphragm, sternum and abdominal muscles, all aid in breathing.

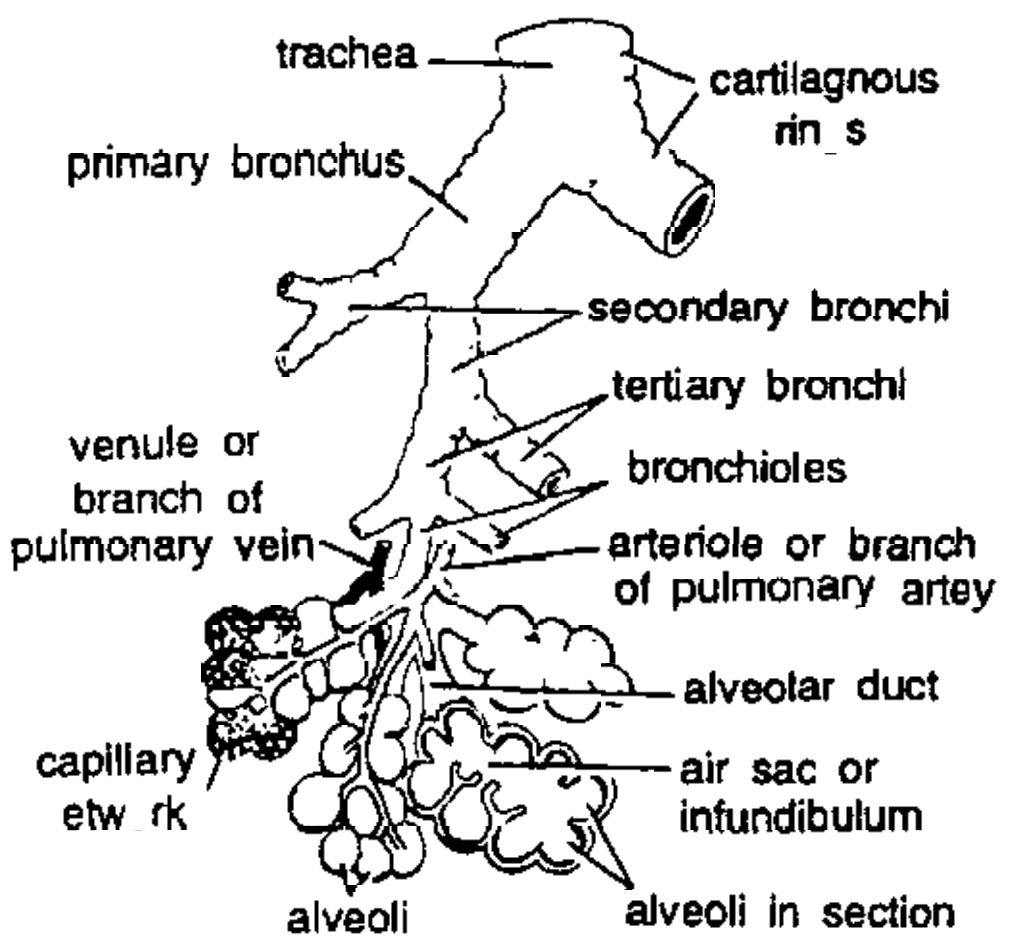

Fig. 6. Mammalian lung. Branching of a bronchus into terminal alveoli.

Accessory Respiratory Organs

Although gills serve as chief respiratory organs of aquatic vertebrates, and lungs serve terrestrial vertebrates in a similar way, other structures present may also provide accessory respiratory mechanism, for taking O_2 directly from water or air.

1. **Yolk sac and allantois.** Practically all embryonic vertebrates use yolk sac with its vitelline circulation for gaseous exchange in addition to absorbing yolk which is used as food. Yolk sac of dogfish embryo and yolk sac placenta of the marsupials, in contact with uterine wall, serve as respiratory devices. In reptiles, birds and mammals, allantois and allantoic (umbilical) vessels also become temporary respiratory organs during embryonic life.

2. **Skin.** In amphibians, respiration is common via moist and naked skin which is highly vascular. Lungless salamanders or plethodonts rely entirely on skin for respiration, since larval gills disappear at metamorphosis and adults fail to develop lungs. Vascular hairy cutaneous projections in the male of so-called African hairy frog, *Astylosternus* serve a respiratory function. The vascular caudal fin of mud-skipper *Periophthalmus*, which remains submerged, also functions as a breathing organ.

3. **Lining epithelium.** In some fishes and aquatic amphibians, the lining of cloaca, rectum, gut or bucco-pharyngeal epithelium is highly vascular and aids in respiration.

4. **Cloacal bladders.** Reptilian skin is cornified and useless in respiration. But, in some aquatic turtles, a pair of thin-walled, lateral and greatly vascular cloacal bladders are continually being filled and emptied of water through vent. These accessory bladders serve as important respiratory organs, especially during submergence for longer durations.

5. **Pelvic gills.** In American lung fish *Lepidosiren*, the bushy, filamentous vascular gills attached to the pelvic fins of male provide fresh oxygen to the guarded eggs.

6. **Opercular gills.** In some fishes with an operculum such as *Acipenser*, *Lepidosteus*, *Polyodon*, *Polypterus* and many teleosts, a series of vascular lamellae with a respiratory function develop on the inner surface of operculum.

7. **Pseudobranchs.** Pseudobranchs in spiracles of elasmobranchs and also in some teleosts are homologous with true gills and regarded as demibranchs of the mandibular arch. However, they are not respiratory as they receive already arterial blood.

8. **Pharyngeal diverticula.** The vascular posterior extensions of pharynx in *Periophthalmus*, *Amphipnous* and *Channa* (= *Ophiocephalus*) serve to breathe atmospheric air during aestivation and emergence out of water for short periods.

9. **Branchial diverticula.** The vascular outgrowths of branchial chamber in *Heteropneustes* (= *Saccobranchus*), *Clarias* and *Anabas* form more complicated aerial accessory respiratory organs.

10. **Swim bladders.** Another important structure serving as a lung in some lower fishes is the swim bladder or air bladder discussed in detail in Chapter 18.

IMPORTANT QUESTIONS

» ***Long Answer Type Questions***

1. Give a comparative account of respiratory organs in the vertebrates studied by you.
2. Write an essay on accessory respiratory organs of vertebrates.

» ***Short Answer Type Questions***

1. Write short note on — (i) Air bladder, (ii) Larval gill, (iii) Pseudobranchs, (iv) Swim bladders.

» *Multiple Choice Questions*

1. Gills and lungs of vertebrates are the derivative of embryonic :
   (a) Pharynx (b) Archenteron
   (c) Heart (d) Kidney
2. A complete gill is called :
   (a) Demibranch (b) Holobranch
   (c) Hemibranch (d) Pseudobranch
3. In bony fishes operculum arises from :
   (a) Hyomandibular (b) Mandible
   (c) Sphenethmoid (d) Hyoid arch
4. Lungs of reptiles are located in :
   (a) Neck (b) Thorax
   (c) Abdomen (d) Tail
5. Respiratory organ of embryonic vertebrates :
   (a) Yolk sac (b) Amnion
   (c) Chorion (d) Egg membrane
6. During submergence in aquatic turtles the accessory respiratory organ is :
   (a) Skin (b) Gill
   (c) Cloacal bladder (d) Air sacs

ANSWERS

1. (a) 2. (b) 3. (d) 4. (c) 5. (a) 6. (c).

55

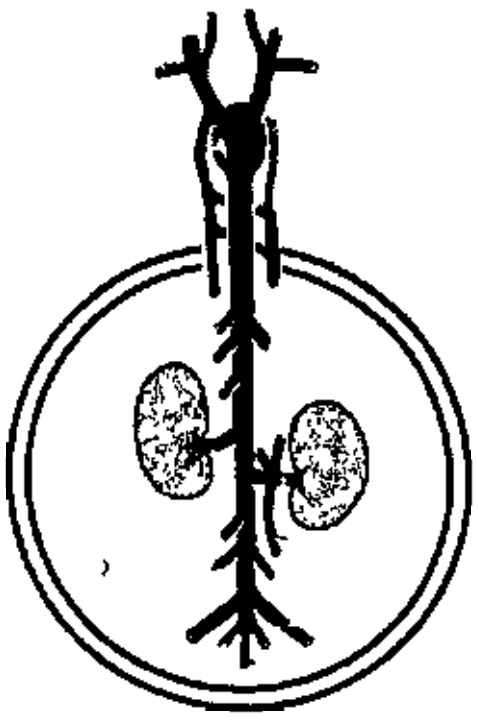

Circulatory System in Vertebrates

In order to carry on vital life processes, all animals, from the simplest protozoans to the most complex vertebrates, required that —

(1) *Food* absorbed through digestive tract and oxygen collected in respiratory organs, must be transported to all parts of the body, continually, for metabolism.

(2) *Waste products* of metabolism (CO_2, nitrogenous wastes, etc.) must be transported from the sites of their productions to excretory organs for their quick elimination from body.

(3) *Hormones* from endocrine tissues, substances for maintaining *homeostasis* or constancy of internal environment, and providing immunity from diseases, must be conveyed to suitable sites for utilization.

For these and other reasons, an adequate internal system for circulating nutrients and other materials throughout the body becomes necessary, called *circulatory system*. In one-celled body of protozoans, distribution occurs through *cyclosis* or streaming movements of cytoplasm. In simple and less active multicellular animals (Porifera, Coelenterata, Helminthes, etc.) exchanges occur by simple diffusion between various adjacent parts of their bodies. But most higher invertebrates and vertebrates are large and active, with most body organs and tissues well removed from exterior or gut. For them, diffusion alone cannot suffice. Thus, they possess a well-developed *circulatory system* for rapid internal transport of gases, nutrients, wastes, etc.

Parts of Circulatory System

Chordates have a completely closed circulatory system (Fig. 1), further distinguished into two systems, *blood vascular* and *lymphatic*, having parts as follows :

1. Blood vascular system. It consists of heart, arteries, veins, capillaries and blood. (i) *Blood* consists of fluid plasma and free cells or blood

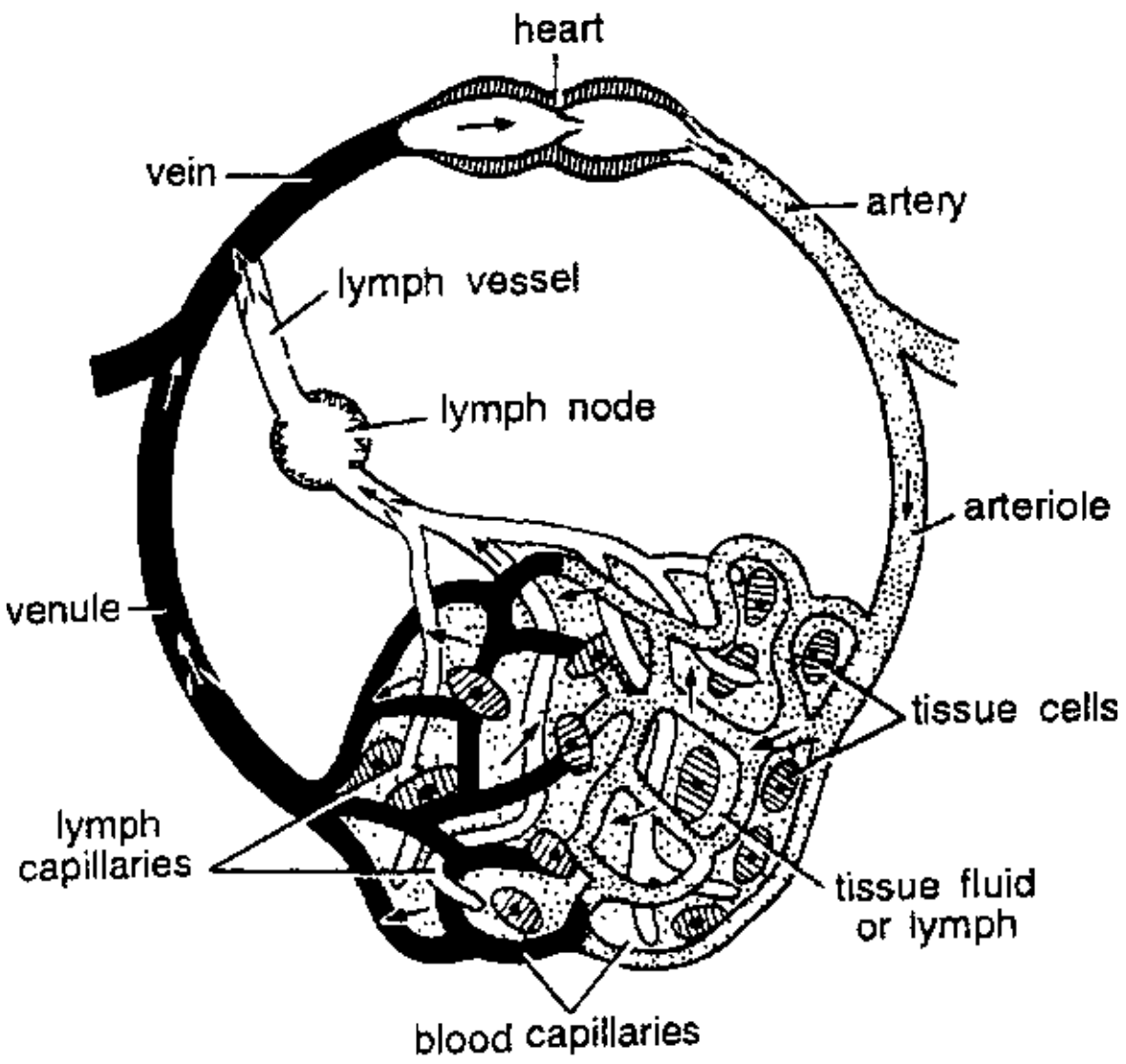

Fig. 1. Fundamental structure and parts of a typical mammalian circulatory system.

corpuscles. (ii) *Heart* is a modified blood vessel with muscular walls. It contracts periodically to pump blood through body. (iii) *Arteries* are blood vessels that carry blood away from the heart. (iv) *Capillaries* are minute tubes with thin walls in tissues, that connect the smallest arteries (arterioles) with the smallest veins (venules). (v) *Veins* carry blood towards heart from capillary networks.

When blood flows through capillaries connected by arteries and veins, the blood vascular system is said to be 'closed', as in annelids and vertebrates. On the other hand, mollusc's and arthropods lack capillaries and have an 'open' or 'lacunar' system. The blood pumped by their heart through blood vessels to various organs, passes through body spaces or sinuses comprising the haemocoel.

2. Lymphatic system. It occurs exclusively in chordates, except cyclostomes and cartilaginous fishes, and consists of lymph and lymph channels. (i) *Lymph* is the *tissue fluid*, lying between and bathing body cells. It is similar to blood plasma but lacks the red blood corpuscles and some proteins. (ii) *Lymph capillaries* forming a network of minute, blind-ending channels, collect lymph. (iii) *Lymph vessels* — larger thin-walled vessels formed by the union of lymph capillaries, and finally emptying into veins. (iv) *Lymph nodes*, found only in mammals on lymph vessels, produce lymphocytes of blood and form an important link in body's defense mechanism.

In cyclostomes and chondrichthyes no lymphatics are present but little sinusoids are found, representing the first stage of development. Bony fishes and all tetrapodes are provides with lymphatic system. But as far as circulation is concerned, it is active in amphibian due to development of *lymph heart*. *Lymphatic glands* first appeared in reptiles and found in birds and mammals as well.

Blood vascular system has undergone some striking changes during the evolution of vertebrates. These are mostly correlated with shift from gills to lungs as the site for external respiration during transition from water to land, and with the development of an efficient, high pressure circulatory system necessary for an active terrestrial life.

Evolution of Heart in Vertebrates

In the embryo, two longitudinal endothelial tubes, formed by mesenchyme in ventral mesentery below archenteron, fuse together to give rise to the heart. The vertebrate heart is built in accordance with a basic architectural plan (Fig. 2). It is a sac-like muscular organ comprising a series of chambers, that receives blood from veins and pumps it through arteries.

[I] Single-chambered heart

Cephalochordata. In a primitive chordate, such as *Branchiostoma*, a true heart is lacking. Instead a part of ventral, aorta below pharynx becomes muscular and contractile. Some zoologists consider it as a *single-chambered heart*.

Progressive modifications of heart from primitive to higher chordates occurs on the following lines :

(1) Cardiac tube forms chambers due to constrictions.

(2) Each chamber tends to divide into two separate chambers due to formations of partitions.

(3) Heart gradually shifts from just behind head (fishes, amphibians) near gills into thoracic cavity (amniotes) with elongation of neck and development of lungs.

[II] 2-Chambered, single circuit venous hearts

Cyclostomes. Simplest conditions of vertebrate heart is seen in cyclostomes (ammocoete larva, lamprey, hagfish). It shows a linear series of 4 chambers : *sinus venosus, atrium, ventricle* and a small *conus arteriosus*, through which blood flows in that sequence. It is present in the common body cavity along with other visceral organs.

Elasmobranchs. Heart of a cartilaginous dogfish is typical and generalized for most fishes. It is a muscular and dorso-ventrally bent, S-shaped tube consisting of 4 chambers arranged in a linear sequence. Of these, sinus venosus and conus arteriosus are *accessory chambers*. Only auricle and ventricle are *true chambers* so that heart is considered *two-chambered* in fishes. Thin-walled *sinus venosus* receives venous blood of body through larger veins (common cardinal and hepatic), serves chiefly as a reservoir and opens anteriorly into atrium through the *sino-atrial aperture* guarded by a pair of valves. *Atrium* is large, thin-walled, elastic and muscular chamber lying dorsal to ventricle. It opens ventrally into ventricle through an *atrio-ventricular aperture* guarded by a pair of valves. *Ventricle* has very thick and muscular walls. It opens into a muscular tube of narrow diameter, the *conus arteriosus*, having a series of semilunar valves. All the valves of heart prevent backflow or regurgitation of blood.

Heart of fishes is enclosed in a small *pericardial cavity* separated from general coelom by a transverse septum. In front of *pericardial cavity*, conus becomes continuous with the ventral aorta. In elasmobranchs, transverse septum is perforated by a pair of openings through which pericardial cavity communicates with coelom.

Teleosts. Heart of bony fishes resembles in all respects that of elasmobranchs. In some Chondrostei *(Polypterus)* and Holostei *(Lepidosteus)*, conus is fairly long with numerous valves. In *Amia*, conus and number of its valves are reduced. While in Teleostei, conus is much reduced, or even absent, as it fuses with ventricle, and retains a single pair of semilunar valves. Instead, the part of ventral aorta in contact with conus becomes greatly enlarged with thick muscular walls, and called *bulbus arteriosus*. It is elastic and inflates like a balloon when the ventricle contracts.

In fishes, heart is small, 2-chambered and with a single circuit of blood circulation. All blood passing only once through heart is non-oxygenated. It is pumped into gills for aeration before distribution to body. Such a heart is termed a *branchial* or *venous heart.*

[III] 3-Chambered transitional hearts

Dipnoi. Correlated with the shift from aquatic (gills) to terrestrial respiration (lungs), heart and aortic arches also become modified. Parallel with the *systemic circulation*, a new shorter *pulmonary circulation* develops so that aerated blood from lungs (or swim bladder), returns directly to the heart without making a detour of the whole body. *Atrium* of lung fishes (and most urodele amphibians) is divided by an incomplete *inter-auricular septum*, perforated by the *foramen ovale*, into right and left chambers or *auricles.* This results in a mixing of oxygenated blood received from lungs into left auricle, and deoxygenated blood from rest of body into right auricle. A partial partition also divides the *ventricle*, while a horizontal septum divides the *conus* of lungfishes into a dorsal and a ventral part.

Amphibians. Amphibians heart (anurans) shows an advance over the piscine heart. A twisting or curving results in dorsal *atrium* shifting anteriorly to ventricle. Similarly, *sinus venosus* opens into the right atrium dorsally instead of posteriorly. The *inter-auricular septum* is complete,

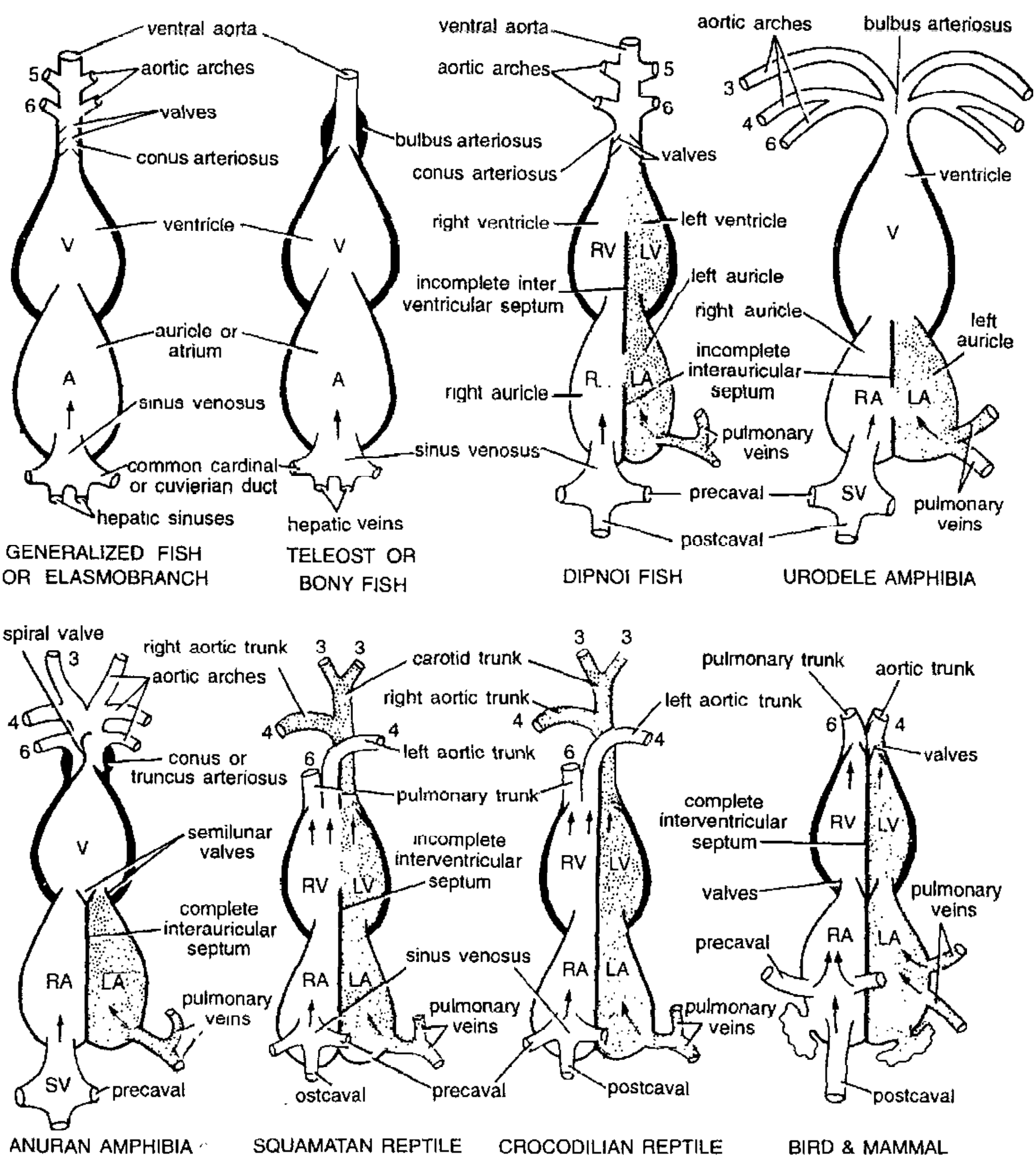

GENERALIZED FISH OR ELASMOBRANCH — TELEOST OR BONY FISH — DIPNOI FISH — URODELE AMPHIBIA

ANURAN AMPHIBIA — SQUAMATAN REPTILE — CROCODILIAN REPTILE — BIRD & MAMMAL

Fig. 2. Successive modifications of heart during evolution in different classes of vertebrates. 1—6 represent aortic arches. Shaded chambers contain mainly oxygenated blood. LA—left auricle, LV—left ventricle. RA—right auricle. RV—right ventricle. SV—sinus venosus.

without foramen ovale. This keeps the oxygenated and deoxygenated bloods separate. *Ventricle* is undivided or single, but its thick muscular wall raised into trabeculae permitting only little mixing of the two bloods. In urodeles, conus is reduced and replaced by a *bulbus arteriosus*. In anurans, from left ventricle, on its anterolateral margins *conus* (or *truncus*) *arteriosus* arises which is prominent and divided by a *spiral valve* which directs deoxygenated blood into pulmonary vessels and oxygenated blood into systemic vessels. The lumen of conus arteriosus is called, pylangium is occupied by spiral valve (= *septum bulbi*). This valve is very complicated in its disposition. It is attached to the walls of conus dorsally and free at other three faces. It divides the lumen of conus arteriosus into two chamber— *cavum pulmocutaneum* and *cavum aorticum.*

Reptiles. Heart of reptiles shows further improvement over that of amphibians. It becomes more strongly muscular. It shows two auricles and two ventricles. In most reptiles, *ventricle* is partially divided by an incomplete *inter-ventricular septum,* which reduces the mixing of oxygenated and deoxygenated blood. In crocodilians, this septum is complete thus making an effective 4-chambered heart, having two auricles and two ventricles. However, complete separation of oxygenated and deoxygenated blood is not achieved. The right and left systemic aortae, carrying arterial and venous bloods, respectively, join to form the dorsal aorta in which the two bloods get mixed before distribution. Besides, a small opening, called *foramen* of *panizza,* connecting the two aortae at their base, brings about some mixing of blood. In crocodiles foramen panizza becomes obliterated. A *sinus venosus* is present in all reptiles, large in turtles, small in snakes and lizards, and distinct internally in crocodiles. Conus and ventral aorta of embryo become split in the adult into three distinct trunks-pulmonary and right and left systemic.

Amphibian heart with only 3 major chambers (2 auricles, 1 ventricle), and reptilian heart with partially 4 chambers (2 auricles, 2 incomplete ventricles), permit a partial mixing of arterial and venous bloods before distribution. Thus, they represent *transitional hearts* showing a midway condition between 2-chambered heart of fishes with a single circulation and 4-chambered hearts of birds and mammals with double circulation and complete separation of arterial and venous bloods.

[IV] 4-Chambered, double circuit pulmonary hearts

Birds and mammals. Birds and mammals have a completely divided *ventricle,* so that their heart is completely 4-chambered (2-auricles, 2 ventricles). Left auricle receives aerated blood from lungs, pours into left ventricle which pumps it to entire body through *systemic circulation.* Right auricle receives deoxygenated blood returning from body, passes it to right ventricle which pumps it to lungs for reoxygenation. Thus there is *double circulation* in which there is no mixing of oxygenated and non-oxygenated blood at all. Such a heart is known as a *pulmonary heart. Sinus venosus* is absent being completely incorporated into right auricle which directly receives two precavals, postcaval. The union of sinus with right auricle in some cases is marked externally by a groove called *sulcus terminalis* and internally by a muscular ridge, *crista terminalis* which separates right auricular chamber (*sinus venerum*) from smaller ventral chamber (*appendix auricular*). Similarly, the left auricle receives blood directly through pulmonary veins. Primitive conus arteriosus is completely replaced by a pulmonary aorta leaving the right ventricle for lungs, and a single systemic aorta leaving the left ventricle for body. All major vessels have valves basally at the point of exit from or entry into heart. Blood from the walls of the heart is brought to the auricle by means of *coronary sinus* in right atrium. The opening of the sinus is guarded by valves called *coronary valve* (= *Thebsian valve*). The inner surface of right auricle wall is marked by small depressions of *Thebesian foramina* in which fine veins directly pass the blood from atrial walls to right atrium. Although, interauricular septum is complete in adults but a fine depression, *fossa ovalis* is present which marks the site of *foramen ovale.* The fossa ovalis is surrounded by a prominent ridge *annulus ovalis.*

Modifications of Aortic Arches in Vertebrates

Basic embryonic plan. In a typical vertebrates embryo, the major arterial channels include a *ventral aorta,* a *dorsal aorta* and usually 6 pairs of *aortic arches* connecting ventral aorta with the dorsal aorta (Fig. 3). Blood leaves the heart through *ventral aorta* which runs forward,

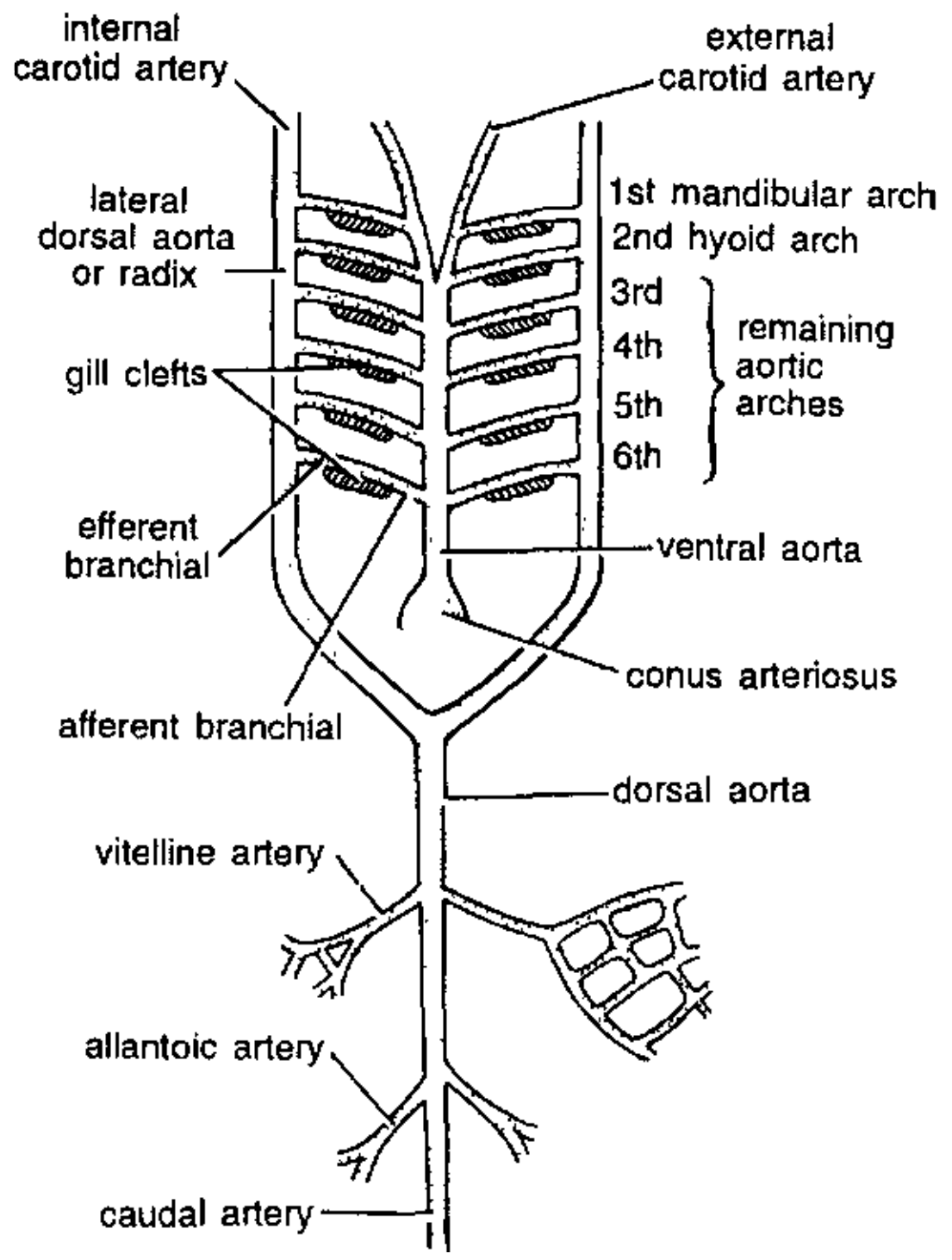

Fig. 3. Basic pattern of chief arterial channels of a typical vertebrate embryo.

midventrally beneath the pharynx and branches anteriorly into a pair of *external carotid arteries* into head. Ventral aorta gives off, at intervals, 6 pairs of *aortic arches* running through the visceral arches. Each *aortic* arch consists of a ventral *afferent branchial artery* carrying venous blood to capillaries in a gill, and a dorsal *efferent branchial artery* taking arterial blood from the gill. All the efferent branchial arteries of the same side dorsally join a *lateral dorsal aorta* or *radix* which is extended into head as the *internal carotid artery*. The two lateral dorsal aortae unite just behind the pharynx to form a single median *dorsal aorta* which continues behind into tail region as *caudal artery*. Branches from these main arterial channels supply all parts of the vertebrate body.

Although arterial system of different adult vertebrates shows major differences, but it is actually built according to the same basic architectural plan as seen in the vertebrate embryo (Fig. 4). The differences are due to increasing complexity of heart on account of a shift from gill respiration to lung respiration. The modifications mainly concern the aortic arches which undergo a progressive reduction in number from lower to higher vertebrates.

Primitive vertebrates. In *Branchiostoma* (amphioxus), nearly 60 pairs of aortic arches are present, connecting the ventral and dorsal aortae. In *Petromyzon*, 7 pairs of aortic arches are found. In other cyclostomes the number varies from 6 *(Myxine)* to 15 pairs *(Eptatretus)*.

Fishes. The primitive elasmobranch *(Heptanchus)* has 7 pairs of aortic arches. Most of the fish embryos present primitive plan with 6 or more pairs of aortic arches, each passing through a gill. But, in adult condition, the number is reduced to 4 or 5. In most sharks (elasmobranchs), only 5 pairs (II, III, IV, V, and VI) are functional. The first gill slit forms the spiracle which is non-functional as a gill. Accordingly the first arch (mandibular) is absent or represented by an efferent pseudobranchial artery. In most teleosts or bony fishes, I and II arches tend to disappear, so that only 4 pairs (III, IV, V and VI) remain functional. In *Polypterus* and lungfishes (Dipnoi), gills are poorly developed, so that a *pulmonary artery* arises from the efferent part of the VI arch on each side and supplies blood to the developing air bladder or lung. In *Protopterus*, the III and IV embryonic arches are uninterrupted by gill capillaries.

In elasmobranchs and lungfishes, each arch forms one afferent and two efferent arteries (by splitting) in each gill. In teleosts or bony fishes, each gill has one afferent and one efferent artery. In tetrapods, true internal gills are absent so that aortic arches do not break up into afferent and efferent arteries. I and II arches totally disappear in all tetrapods.

Amphibians. With the introduction of lungs as main respiratory organs and the diminishing importance of gills, the aortic arches of amphibians show a modification from those of fishes.

Urodeles or the tailed amphibians live in water and retain external gills permanently in

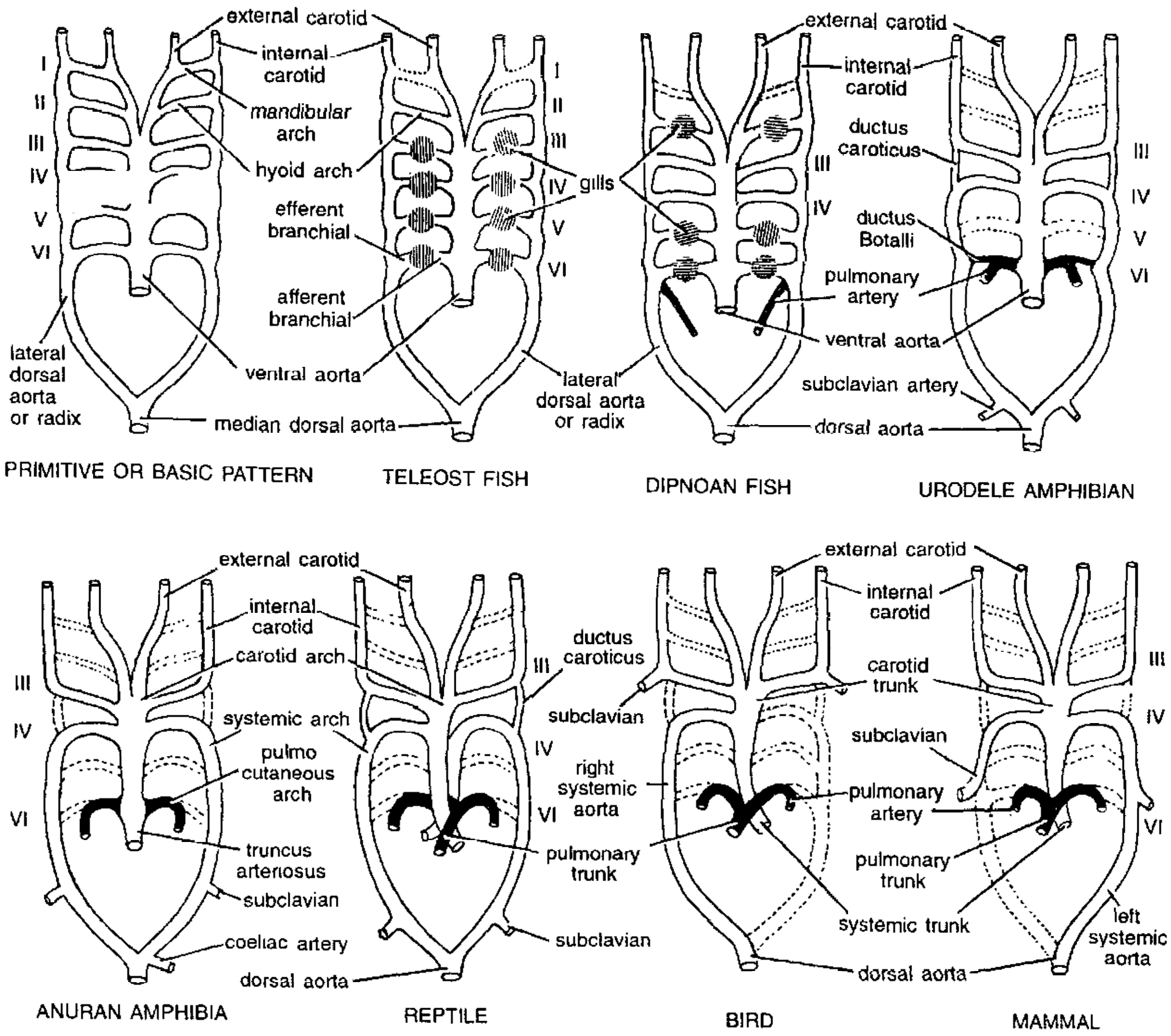

PRIMITIVE OR BASIC PATTERN TELEOST FISH DIPNOAN FISH URODELE AMPHIBIAN

ANURAN AMPHIBIA REPTILE BIRD MAMMAL

Fig. 4. Modification of aortic arches in respresentative vertebrates.

addition to lungs. Accordingly, their aortic system shows only partial shift from condition in fishes. 4 pairs of arches (III to VI) are usually present, although in some forms (*Necturus, Siren, Amphiuma)*, V arch is incomplete, reduced or absent. Thus tailed amphibians show transition from 4 to 3 pairs of aortic arches. III arch forms the *carotid arches*, IV the *systemic arches*. The radix or lateral aorta between III & IV arches may persist as a vascular connection termed *ductus caroticus*. VI arch on either side becomes the *pulmocutaneous artery* or *arch*, supplying blood to skin and lungs. However, it also retains connection with radix aorta called *ductus Botalli* or *ductus arteriosus*.

In the larval stage of an anuran or tailless amphibian, such as frog tadpole, arrangement of aortic arches is similar to an adult urodele, due to gill respiration. At metamorphosis, with loss of gills, aortic arches I, II and V disappear altogether. Ductus caroticus also disappears so that the III or carotid arch takes oxygenated blood only to head region. IV or systemic arch on each side continues to dorsal aorta to distribute blood elsewhere except head and lungs. Ductus arteriosus also disappears so that VI or pulmocutaneous arch supplies venous blood exclusively to lungs and skin for purification. Thus, adult anurans exhibit only 3 functional arches, (III, IV and VI) which are also retained by the amniotes or higher vertebrates.

Reptiles. Reptiles are fully terrestrial vertebrates in which gills disappear altogether and replaced by lungs. Only 3 functional arches (III, IV and VI) are present. But elongation of neck, posterior shifting of heart and partial division of ventricle brings about certain innovations in the aortic system.

(1) Entire ventral aorta and conus split forming only 3 trunks-two aortic or systemic and one pulmonary.

(2) *Right systemic arch* (IV) arises from left ventricle carrying oxygenated blood to the *carotid arch* (III) to be sent into head.

(3) *Left systemic arch* (IV) leads from right ventricle carrying deoxygenated or mixed blood to the body through dorsal aorta.

(4) *Pulmonary trunk* (VI) also emerges from right ventricle carrying deoxygenated blood to the lungs for purification.

(5) Ductus caroticus and ductus arteriosus are absent. But, ductus caroticus is present in certain snakes and lizards (*Uromasitx*), ductus arteriosus in some turtles, and both in *Sphenodon.* Reptiles also remain cold-blooded, like amphibians and fishes, due to mixing of blood.

Birds and mammals. Birds and mammals are warm-blooded because in both the ventricle is completely divided so that there is no mixing of oxygenated and unoxygenated bloods. As usual, 6 arches develop in the embryo, but only 3 arches (III, IV, VI) persist in the adult. Other features are as follows —

(1) Ventral aorta is replaced by two independent aortae or trunks-systemic and pulmonary.

(2) Arch IV is represented by a single *systemic aorta*, right in birds and left in mammals, emerging from left ventricle and carrying oxygenated blood. Uniting with the radix aorta of its side it forms the dorsal aorta.

(3) The only remaining part of the other lost systemic arch is represented by a *subclavian artery*, on left side in birds and on right side in mammals.

(4) Arch III with remnants of lateral and ventral aortae represents *carotid arteries*, which arise from systemic aorta.

(5) Arch VI forms a single *pulmonary trunk* taking deoxygenated blood from right ventricle to the lungs.

(6) Embryonic *ductus caroticus* and *ductus arteriosus* also disappear. The latter closes but persists until hatching or birth in some cases as a *thin ligament of Botalli* or *ligamentum arteriosum.*

Venous System

Deoxygenated or venous blood from different parts of the body is returned to the heart via veins. Like arteries, the veins of all vertebrates also follow a basic pattern or fundamental plan.

[I] Embryonic veins

The venous system in early embryonic life of all vertebrates is relatively simple, similar and in accordance with the basic pattern. Most of the veins are paired and symmetrically arranged. The major basic embryonic veins include : (i) *Cardinals* (anterior, posterior, and common cardinal or ductus Cuvieri), (ii) *lateral abdominal*, (iii) *vitelline*, (iv) *subintestinal*, and (v) *caudal.*

[II] Modifications of veins in vertebrates

Modifications in adult vertebrates occur by either deletions or additions of some veins to the basic embryonic pattern (Fig. 5). Modifications are few in elasmobranchs but more numerous in tetrapods. In vertebrates, veins can be arranged in three distinct categories– *systemic* or *somatic*, *renal portal* and *hepatic portal.* A fourth category of *pulmonary veins* and *postcaval veins* in added in lungfishes and tetrapods.

1. Systemic veins. Systemic or somatic veins collect blood from all parts of the body and empty into sinus venosus of the heart.

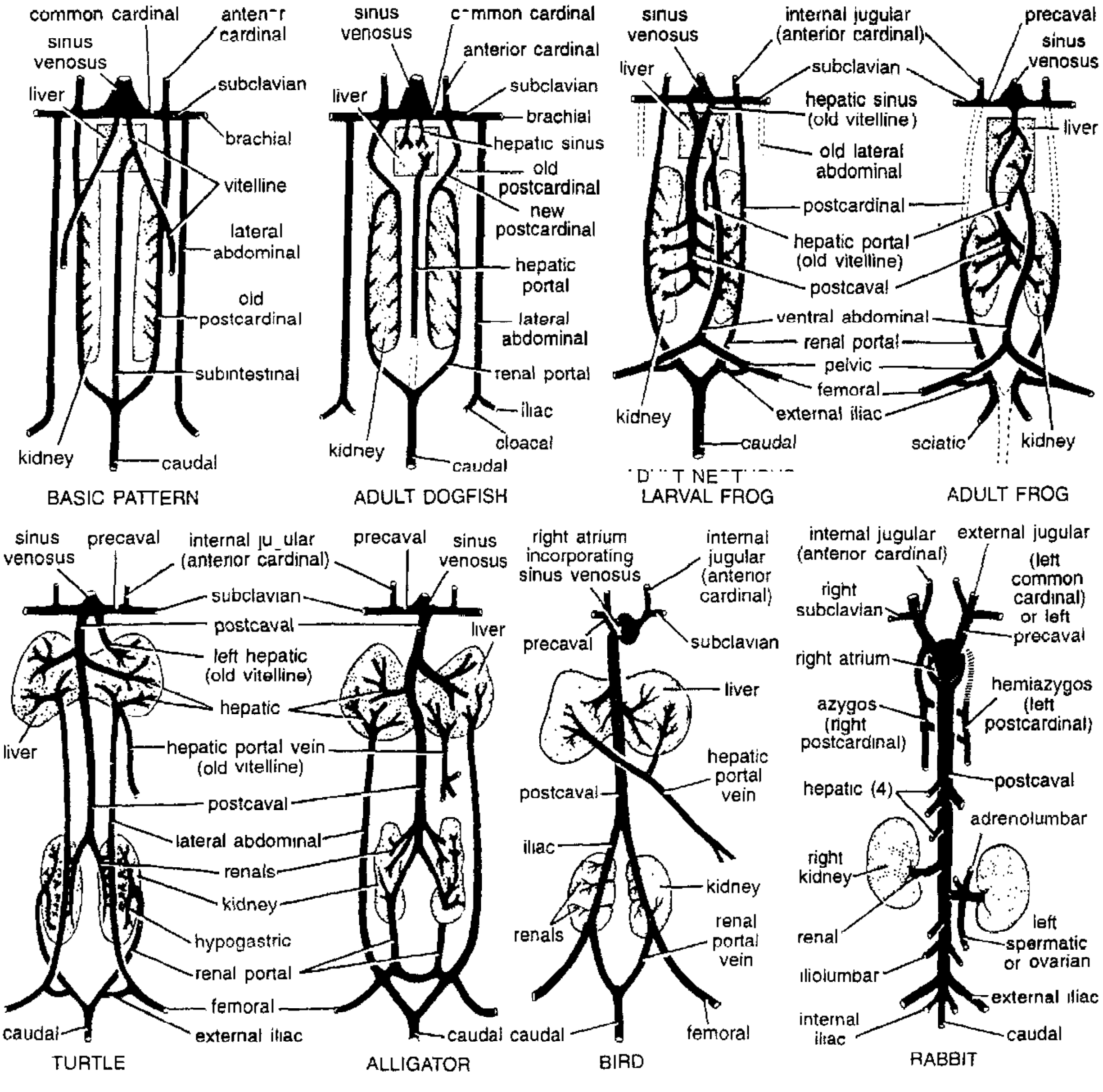

Fig. 5. Modifications of venous system in representative vertebrates. Broken line respresent embryonic vessels that have disappeared in the adult.

(a) Elasmobranchs. In adult cartilaginous fishes (dogfish), venous system is almost a blueprint of the basic architectural plan of the embryo. A few larger veins expand to form thin-walled *sinuses*. Blood from head and posterior region of body is collected by large, paired *anterior* and *posterior cardinal veins* respectively. On either side they open into the *common cardinal* or *ductus Cuvieri*, that passes inwards through transverse septum to enter the sinus venosus of heart. In fishes and salamanders, an *inferior jugular vein* also collects blood on either side from ventral part of head to join the common cardinal. In embryo, posteriorly, the two posterior cardinal veins remain continuous with a *caudal vein* collecting blood from tail. Each posterior cardinal, or *postcardinal*, runs anteriorly along the outer margin of kidney, draining it through a series of *renal veins*, before joining the common cardinal. In adult dogfish, the old postcardinals become interrupted near anterior ends of kidneys. Instead new postcardinals (earlier subcardinal channels) develop along the inner margins of kidneys which they drain.

Blood from lateral wall and pelvic fin on either side is returned through a *ventral* or *lateral abdominal vein*. It receives a *branchial vein* from pectoral fin forming a short *subclavian vein* enters the common cardinal of its side. Abdominal veins are absent in bony fishes or teleosts. In some lungfishes (*Neoceratodus*), two abdominals fuse to form a single *ventral abdominal vein* which terminates into sinus venosus. Blood from liver is taken to sinus venosus through a pair of *hepatic veins* or *sinuses*.

(b) Tetrapods. Embryonic tetrapods also exhibit anterior, posterior and cardinal veins. In adult tetrapods, anterior cardinals persist as the *internal jugular veins*. The *inferior jugular veins* are absent. Common cardinals become the anterior venae cavae or *precavals* which join sinus venosus (amphibians, reptiles) or directly enter the right auricle of heart (birds, mammals) when a sinus venosus is lacking. In some mammals, (man, cat) left precaval disappears, so that blood of left side enters right precaval through a *branchiocephalic* vessel.

In adult *Necturus* and larval frog, the *postcardinals* retain primitive condition, joining caudal vein posteriorly and common cardinal (precaval) anteriorly. In tetrapods, anterior part of each postcardinal disappears but partially present in reptiles, birds and mammals under new names, such as *azygos*, *hemizygos* and so forth. Whereas, the posterior part of postcardinal, in continuation with the caudal vein, forms the *renal postal vein*.

With the suppression of postcardinals, a new vessel, called inferior vena cava or *postcaval*, develops in tetrapods. It is a large median vessel between the two kidneys originating in the embryonic subcardinal venous plexus. It conveys blood of hind limbs, tail, kidneys, and liver into sinus venosus (amphibians, reptiles) or into right atrium (birds, mammals).

In amphibians, two embryonic ventral or anterior abdominal veins become fused in the adult to form a single *median ventral abdominal vein*. But it terminates anteriorly into liver and no longer drains the forelimbs. In reptiles, abdominal veins remain paired throughout life and also terminate into liver. They remain connected anteriorly with the hepatic portal system, and posteriorly with the renal portal system (by external iliac). In birds, they are modified into epigastric and coccygeo-mesenteric veins. In mammals, abdominal veins are absent except in spiny anteater *(Tachyglossus)*.

In air-breathing vertebrates, *pulmonary veins* drain the lungs and enter the left auricle. In lungfishes and amphibians, right and left vessels unite to form a common pulmonary vein opening into right auricle.

2. Renal portal system. Blood collected from capillaries in different parts of body is returned directly to the heart through systemic veins and their tributaries. However, in some cases, the returning blood is forced to run through a secondary capillary network in kidneys or liver before being sent to the heart. This is called *portal circulation*. The vein carrying blood from one set of capillaries to another is termed a *portal vein*. All the constituents in a portal circulation together form a *portal system*, named after the organ of body having the secondary capillary· network. Two portal systems exist in vertebrates : (i) *renal portal* and (ii) *hepatic portal*.

Renal portal system is not universally present in all vertebrates. Cyclostomes have no renal portal system. In vertebrates embryos, *caudal vein* trifurcates anteriorly into a *subintestinal* and two *postcardinal veins*, (basic pattern). In fishes, connection of caudal vein with subintestinal is lost, while the anterior parts of postcardinals are suppressed. As a result, the persistent posterior parts of postcardinals become *renal portal veins* which pour all blood from tail into kidneys through afferent renal veins. Inside kidneys, they contribute blood to the capillary network surrounding the mesonephric tubules, but never to the glomeruli. Thus renal portal system drains only the tail in fishes.

In amphibians and reptiles, an *external iliac* vein connects the renal portal and abdominal veins, so that the renal portal system drains the tail as well as the hind limbs. In tailless amphibians or anurans (frog), it drains only hind limbs, while in snakes, having no limbs, it drains only the tail. In *Necturus*, renal portal vein is directly continuous with postcardinal, as in the basic pattern.

In crocodilians and birds, renal portal system is degenerate and bypasses the kidneys. Only a very little venous blood enters the capillaries in kidneys while most blood from tail and hind limbs passes nonstop through kidneys and leads directly into the postcaval. In mammals, renal portal system is completely absent, except in monotremes, since blood from tail and hind limbs is drained solely by the postcaval.

Significance. During metabolic activities in the body certain toxic or harmful end products such as urea, uric acid, ammonia, etc., are formed. Renal portal system sends blood from hinder body region directly to the kidneys for the removal of these waste products.

3. Hepatic portal system. Hepatic portal system is of universal occurrence and essentially similar in all vertebrates. In the embryo, the first venous channels to form are a pair of *vitelline veins* (basic pattern) arising from the yolk sac or midgut to enter the sinus venosus of heart. Caudal vein from tail is continued forward beneath the digestive tract as a subintestinal vein, which usually joins the left vitelline vein. As liver develops, vitelline veins unite together forming a single *hepatic portal vein* in lesser omentum. The subintestinal vein also loses connection with caudal vein to become a part of hepatic portal system. It drains different parts of digestive tract (yolk sac, stomach, intestine, etc.), its various derivatives (pancreas, gall bladder, rectal gland, etc.) and spleen, and passes it on to the sinusoids in liver. In adult sharks, vitelline veins remain paired and form *hepatic sinuses.*

Significance. Intestinal capillaries absorb several kinds of dissolved food material, except fats, from alimentary canal. These are carried in blood through hepatic portal vein to liver to be temporarily stored up until required. Carbohydrates and sugars are converted into glycogen to be stored in liver cells. If all the sugar remains in circulation, the concentration of blood sugar may go up leading to diabetes. Stored sugar from liver cells is released whenever sugar content of blood drops below normal, which may otherwise lead to unconsciousness. Liver also converts proteins and amino-acids into urea and renders carbolic acid, cresol, indol, ammonia, etc., harmless.

IMPORTANT QUESTIONS

» *Long Answer Type Questions*

1. Trace the evolution of heart in vertebrate series.
2. Give a comparative account of heart in vertebrate series.
3. Give a comparative account of hearts and aortic arches in reptiles, birds and mammals
4. Describe the embryonic arterial and aortic arches of vertebrates and discuss their modifications in different groups of vertebrates.

» *Short Answer Type Questions*

1. Write short notes on— (i) Branchial or venous heart, (ii) Ductus Botalli, (iii) Ductus caroticus, (iv) Foramen of Panizza, (v) Hepatic portal system, (vi) Renal portal system, (vii) Truncus arteriosus.

» *Multiple Choice Questions*

1. Circulatory system does not :
   (a) Transports nutrients
   (b) Transports excretory products
   (c) Transports hormones
   (d) Transfers impulses
2. Smallest arteries are connected to smallest veins by :
   (a) Arterioles (b) Muscles
   (c) Capillaries (d) Venules
3. In urodeles conus is replaced by :
   (a) aorta (b) Vena cava
   (c) Bulbus arteriosus (d) Foramen ovale
4. The union of sinus venosus with right auricle in mammals is marked externally by :
   (a) Sulcus terminalis (b) Crista terminalis
   (c) Sinus venarum (d) Appendix auriculae
5. The opening of coronary sinus is guarded by :
   (a) Besian valve (b) Mitral valve
   (c) Semilunar valve (d) Tricuspid valve

ANSWERS

1. (d) 2. (c) 3. (c) 4. (a) 5. (a).

56

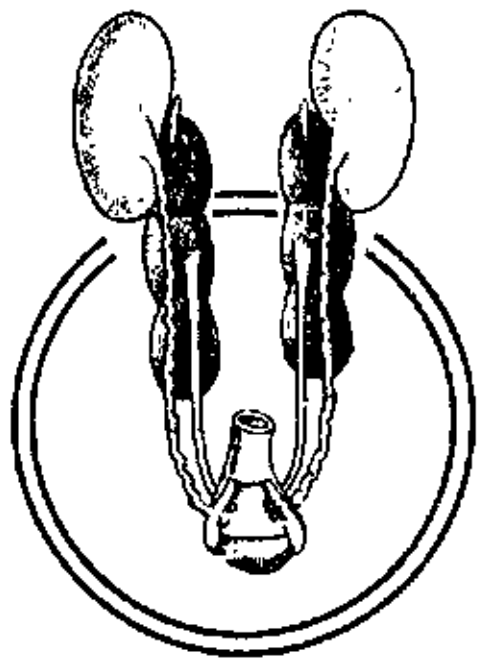

Urinogenital System in Vertebrates

Urinary system of vertebrates includes *kidneys* and their ducts, while reproductive system includes male and female *gonads* and their ducts. Kidneys excrete harmful metabolic nitrogenous wastes and regulate the composition of body fluids, while reproductive organs perpetuate the species. Thus, kidneys and gonads remain functionally unrelated. However, the two systems are intimately related morphologically in vertebrates because the male urinary ducts are also used for discharging gametes. For this reason, it is more convenient to treat and describe the two systems together as the *urogenital* or *urinogenital system*.

Vertebrate Kidneys and Ducts

1. Basic structure and origin. Vertebrate kidneys are a pair of compact organs, lying dorsal to coelom in trunk region, one on either side of dorsal aorta. They are all built in accordance with a basic pattern. Each kidney is composed of a large number of units called *uriniferous tubules* or *nephrons*. Their number, complexity and arrangement differ in different groups of vertebrates.

Kidney tubules arise in the embryo in a linear series from a special part of mesoderm called *mesomere* or *nephrotome* (Figs. 1, 5 & 6). It is the ribbon-like intermediate mesoderm, running between segmental mesoderm (epimere) and lateral plate mesoderm (hypomere) on either side along the entire trunk from heart to cloaca. A uriniferous tubule is differentiated into three parts : *peritoneal funnel, tubule* and *Malpighian body*.

(a) Peritoneal funnel. Near the free end of a uriniferous tubule is a funnel-like ciliated structure called *peritoneal funnel.* It opens into coelom (splanchnocoel) by a wide aperture, the *coelomostome* or *nephrostome*, for draining wastes from coelomic fluid. Nephrostomes are usually confined to embryos and larvae and considered vestiges of a hypothetical primitive kidney.

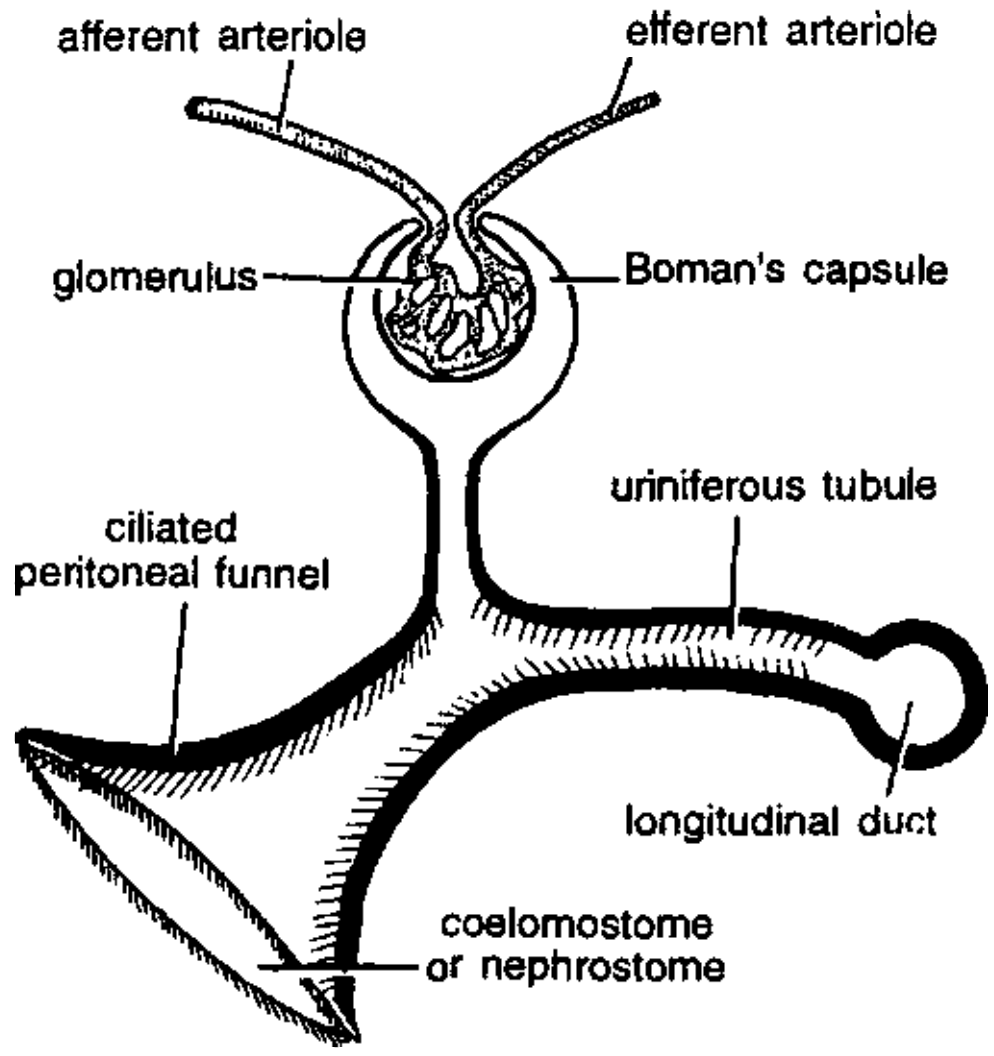

Fig. 1. Structure of an embryonic kidney tubule.

(b) Malpighian body. A tubule begins as a blind, cup-like, hollow, double-walled *Bowman's capsule*. It encloses a tuft of blood capillaries, called *glomerulus*. It is supplied blood by a branch of renal artery, called *afferent glomercular* arteriole. An *efferent glomerular arteriole* emerges out of glomerulus to join the capillary network surrounding the tubule.

Bowman's capsule and enclosed glomerulus together form a *renal corpuscle* or *Malpighian body*. Encapsulated glomeruli are termed *internal glomeruli* which are common. Those without a capsule and suspended freely in coelomic cavity are called *external glomeruli* (embryos and larvae). Capsules without glomeruli are termed *aglomerular*, such as found in embryos, larvae and some fishes.

(c) Tubule. Malpighian bodies filter water, salts and other substances from blood. During passage through tubules more substances are secreted into filtrate, while some are reabsorbed. All the tubules of embryonic kidney are convoluted ductules that conduct the final filtrate to a *longitudinal duct* which opens behind into embryonic cloaca.

2. Archinephros. *Archinephros* is the name given to the hypothetical primitive kidney of ancestral vertebrates (Fig. 2). It may be regarded as a complete kidney or *holonephros* as it extended the entire length of coelom. Its tubules were segmentally arranged, one nephron for each body segment. Each tubule opened by a peritoneal funnel or nephrostome into coelom. Near each nephrostome was suspended in coelom an external glomerulus (without capsule). All the tubules were drained by a common longitudinal *Wolffian* or *archinephric duct* opening behind into cloaca.

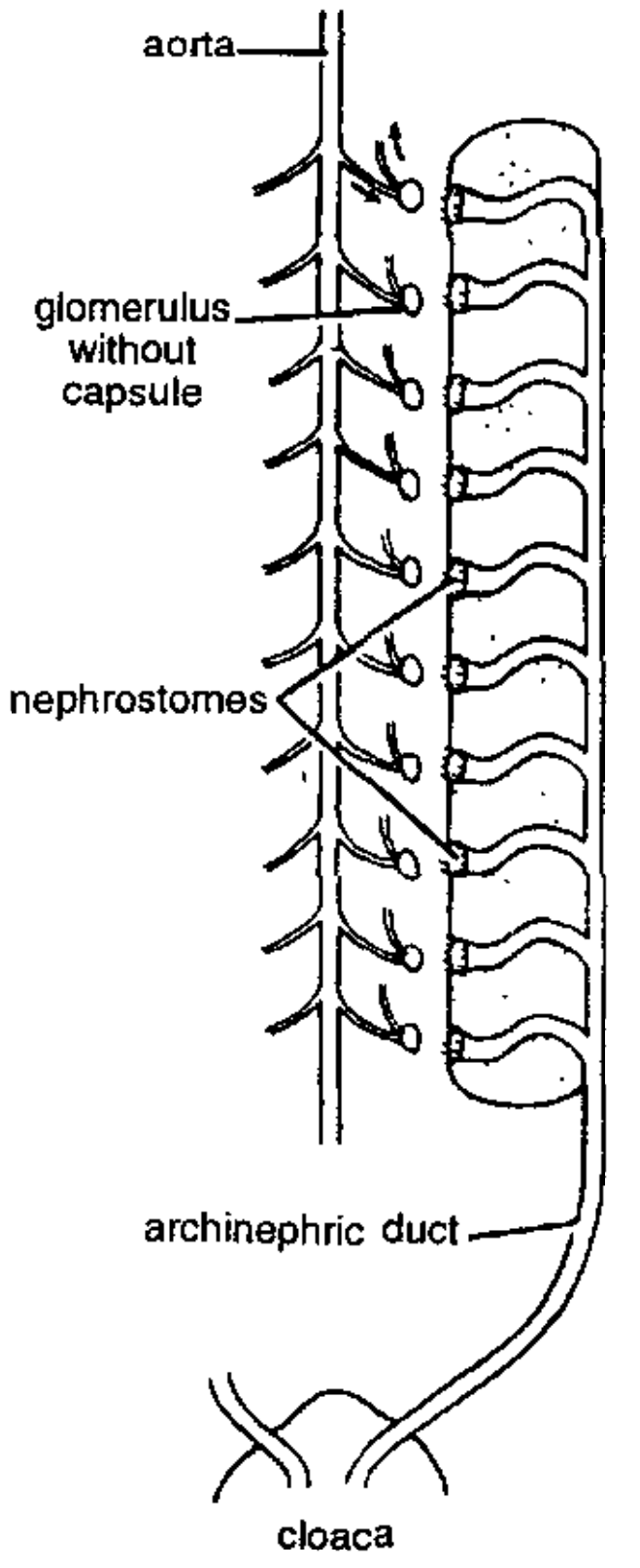

Fig. 2. Hypothetical primitive ancestral vertebrate kidney or archinephros.

Such a hypothetical archinephros is found today in the larvae of certain cyclostomes (*Myxine*), but not in any adult vertebrate. It is supposed to have given rise to all the kidneys of later vertebrates during the course of evolution. Modern vertebrates exhibit three different kinds of adult kidneys : *pronephros, mesonephros* and *metanephros*. It is supposed that these represent the sequence or three successive stages of

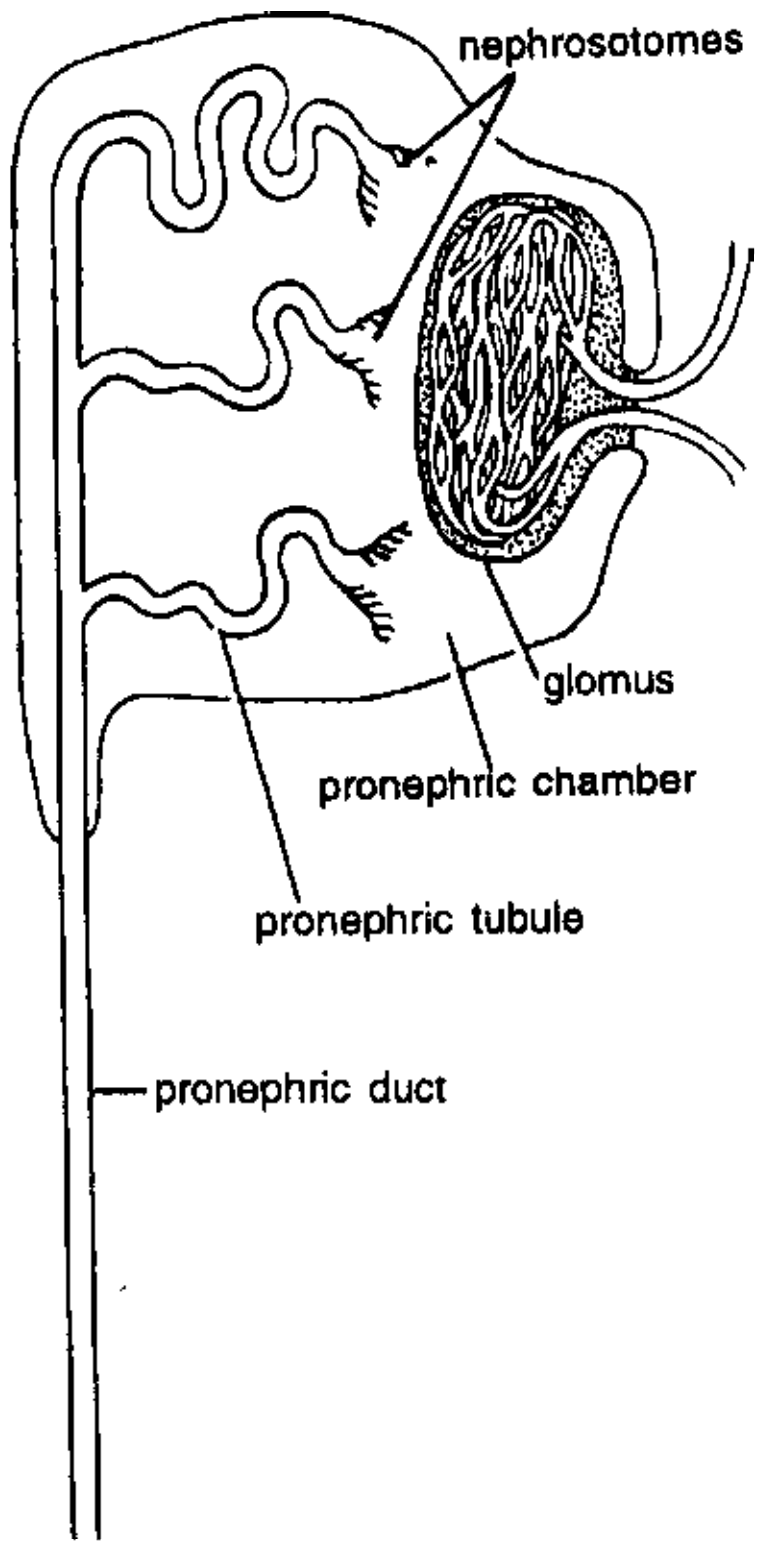

Fig. 3. Encapsulated pronephric kidney of 15 mm. frog larva.

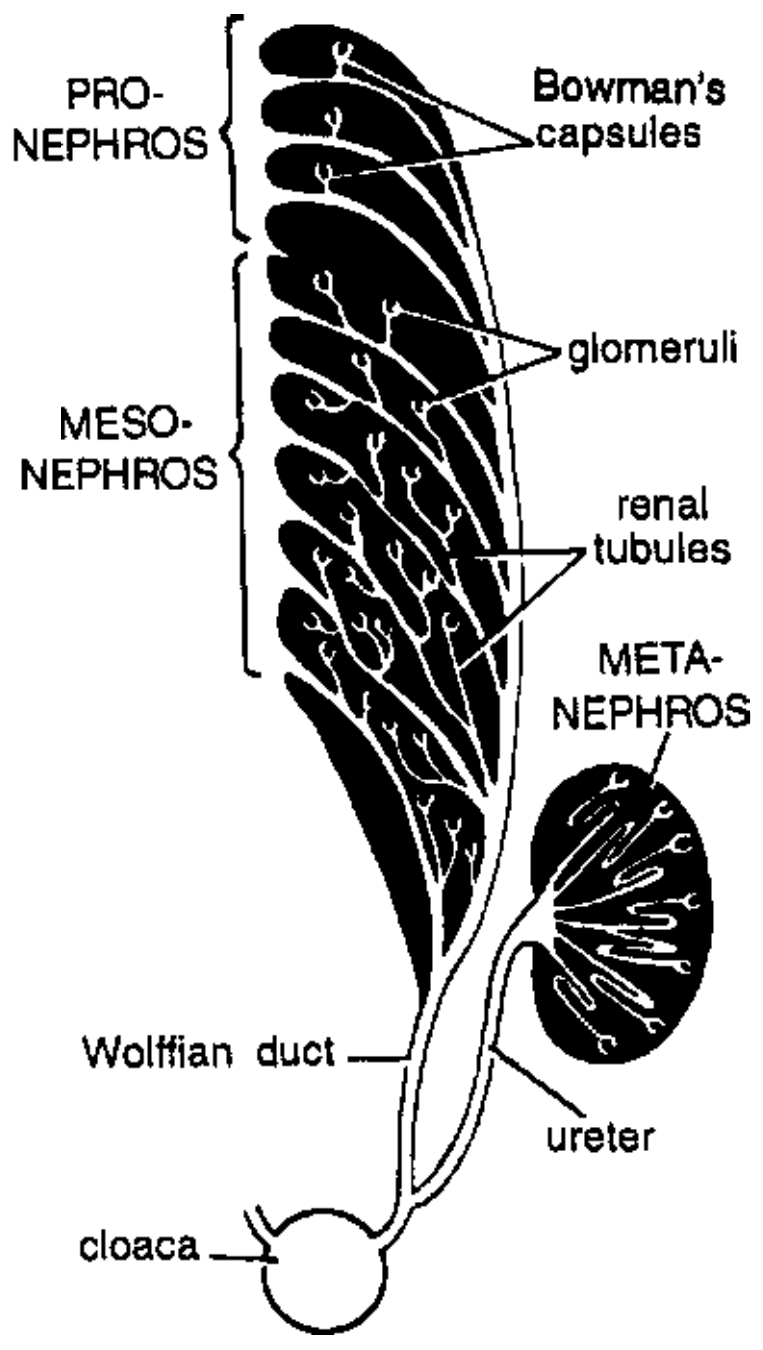

Fig. 4. Diagrammatic plan of pronephros, mesonephros and metanephros in vertebrates.

development of the ancestral archinephros, and all the three are never functional at the same time.

3. Pronephros. In the embryos of all vertebrates, the first kidney tubules appear dorsal to the anterior end of coelom, on either side. These are called *pronephros* as they are first to appear (Fig. 3). Pronephros is also termed *head kidney* due to its anterior position immediately behind the head. A pronephros consists of 3 to 15 tubules segmentally arranged, one opposite each of the anterior mesodermal somites. There are only 3 pronephric tubules in frog embryo, 7 in human embryo and about a dozen in chick embryo. Each tubule opens into coelom by a funnel or nephrostome. Also projecting into coelom near each tubule and not connected with it is an external or naked glomerulus without capsule. In some cases, glomeruli unite to form a single compound glomerulus, called *glomus*. Glomus and tubules become surrounded by a large *pronephric chamber* derived from pericardial or pleuroperitoneal cavity. Originally each tubule has its individual external aperture, but secondarily, all tubules of a pronephros open into a common *pronephric duct*, leading posteriorly into the embryonic cloaca.

Pronephros is functional, if at all, only in embryonic or larval stage. It is mostly transitory and soon replaced by the next stage or mesonephros. However, a pronephros is retained throughout life in adult cyclostomes and a few teleost fishes, but it is nonurinary and mostly lymphoidal in function.

4. Mesonephros. In the embryo, a mesonephros develops from the middle part of intermediate mesoderm, posterior to each pronephros soon after its degeneration (Fig. 4). At first, the new mesonephric tubules join the existing pronephric duct and are segmentally disposed. Later on the tubules multiply by budding so that their segmental arrangement is disturbed due to increased number of tubules per segment. Tubules of pronephros and mesonephros develop similarly

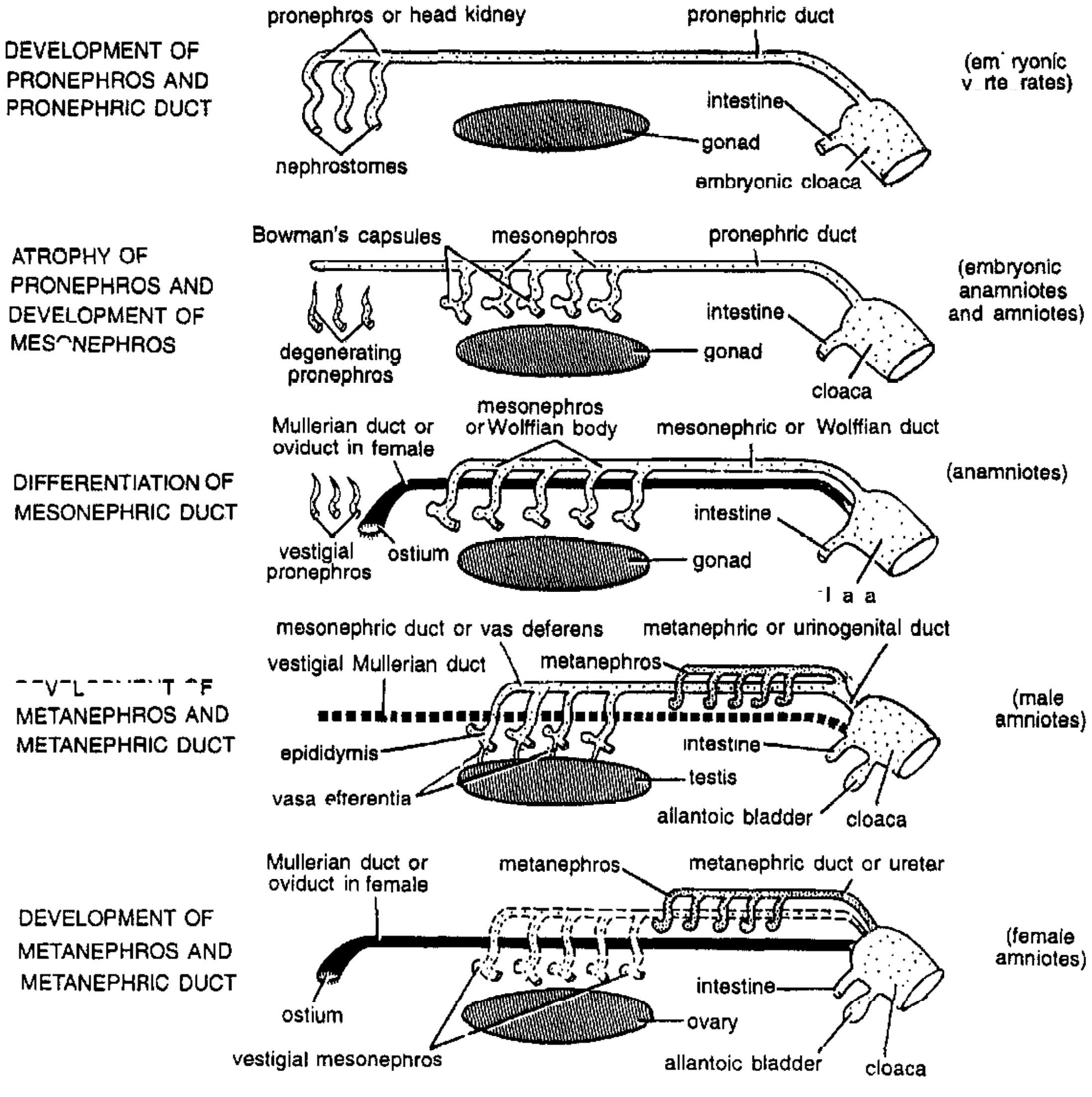

Fig. 5. Evolution of kidney in vertebrate.

and are homologous. However, mesonephros is functionally better than pronephros because mesonephric tubules are more numerous, longer and develop internal glomeruli enclosed in capsules forming Malpighian bodies. Thus, they remove liquid wastes directly from glomerular blood rather than indirectly from coelomic fluid as in case of a pronephros. The mesonephros is also termed *Wolffian body.* With disappearance of pronephros, the old pronephric duct becomes the *Wolffian* or *mesonephric duct.*

In amniotes (reptiles, birds and mammals), mesonephros is functional only in the embryos, replaced by metanephros in the adults. In fishes and amphibians, mesonephros is functional both in embryos as well as adults. In sharks and caecilians, tubules extend posteriorly throughout the length of coelom. Such a kidney is sometimes called a *posterior kidney* or *opisthonephros.* Whereas in adult anurans, urodeles and embryonic amniotes, the mesonephros does not extend posteriorly. Mesonephric kidney is not metameric, but in myxinoids it is segmental and sometimes called a *holonephros*. Nephrostomes are generally lacking in mesonephros of embryonic amniotes.

5. Metanephros. The functional kidney of higher vertebrates or amniotes is a *metanephros*. It is formed from the posterior end of the nephrogenic mesoderm which is displaced somewhat anteriorly and laterally. When metanephric tubules develop, all the mesonephric tubules disappear except those associated with the testis in male and forming vasa efferentia. The adult kidney (metanephros) of amniotes differs from that of anamniotes (mesonephros or opisthonephros) chiefly in :

(1) Its origin from only caudal end of nephrogenic mesoderm.

(2) In greater multiplication and posterior concentration of nephrons or tubules. They are particularly very large in number and highly convoluted in birds and mammals, hence the large size of kidney. It is estimated that each kidney of man is composed of about 1 million nephrons. The high rate of metabolism yields a large amount of wastes to be excreted.

(3) In developing a new urinary duct, called *metanephric duct* or *ureter*. It is budded off from the base of the Wolffian duct (mesonephric duct). It grows anteriorly and dorsally, and eventually the metanephric tubules open into it. Its dilated distal tip forms *pelvis* which forks several times to become the *collecting tubules*. Its proximal portion becomes the *metanephric duct* or *ureter* that empties into cloaca or urinary bladder in mammals.

(4) The mammalian metanephros shows greatest organization of all, with several additional features. A thin, U-shaped *loop* of *Henle* forms between proximal and distal convolutions of a metanephric tubule. Such loops are absent in reptiles and rudimentary in birds. Kidney shows an outer *cortex* with concentration of renal corpuscles, and an inner *medulla* having collecting tubules and loops of Henle, which are aggregated into one or several *pyramids* tapering into pelvis. Mammalian kidneys do not receive afferent venous blood supply as there is no renal portal system.

Urinary Bladders

Most vertebrates have a urinary bladder to store urine before it is discharged. However, it is lacking in cyclostomes, elasmobranchs, some lizards, snakes, crocodilians and most birds. In most fishes it is simply a terminal enlargement of mesonephric ducts and called a *tubal bladder*. In Dipnoi, it evaginates from dorsal wall of cloaca and is probably homologous to the rectal gland of elasmobranchs. In tetrapods, it evaginates from the ventral wall of cloaca. In amphibians, it is termed a *cloacal bladder*. In amniotes, the adult bladder is derived from the proximal part of embryonic allantois, hence called an *allantoic bladder*.

Kidney ducts or ureters generally open dorsally into cloaca. But in mammals, except monotremes, the ureters lead directly into the urinary bladder which opens to outside through a short tube, the *urethra*. Mammals lack a cloaca as the dorsal part of embryonic cloaca forms the rectum and the ventral part becomes the urethra.

Gonads and their Ducts

Reproduction is *sexual* in vertebrates, and the sexes are *separate* (dioecious) with the exception of hagfishes and a few bony fishes having a *hermaphrodite* gonad. Reproductive glands or gonads of males are called *testes* which produce the male gametes called *sperm*. Female gonads are called *ovaries* which produce *ova*. In the embryo, gonads originate as a pair of thick elevated folds or *genital ridges* of coelomic epithelium from the roof of coelom, one on either side of the dorsal mesentery. Genital ridges are much longer than the functional adult gonads, suggesting that in the ancestral vertebrates the gonads extended the whole length of the pleuroperitoneal cavity. The functional adult gonad is derived from the middle or *gonal* part of genital ridge, while its anterior *progonal* and posterior *epigonal* parts remain

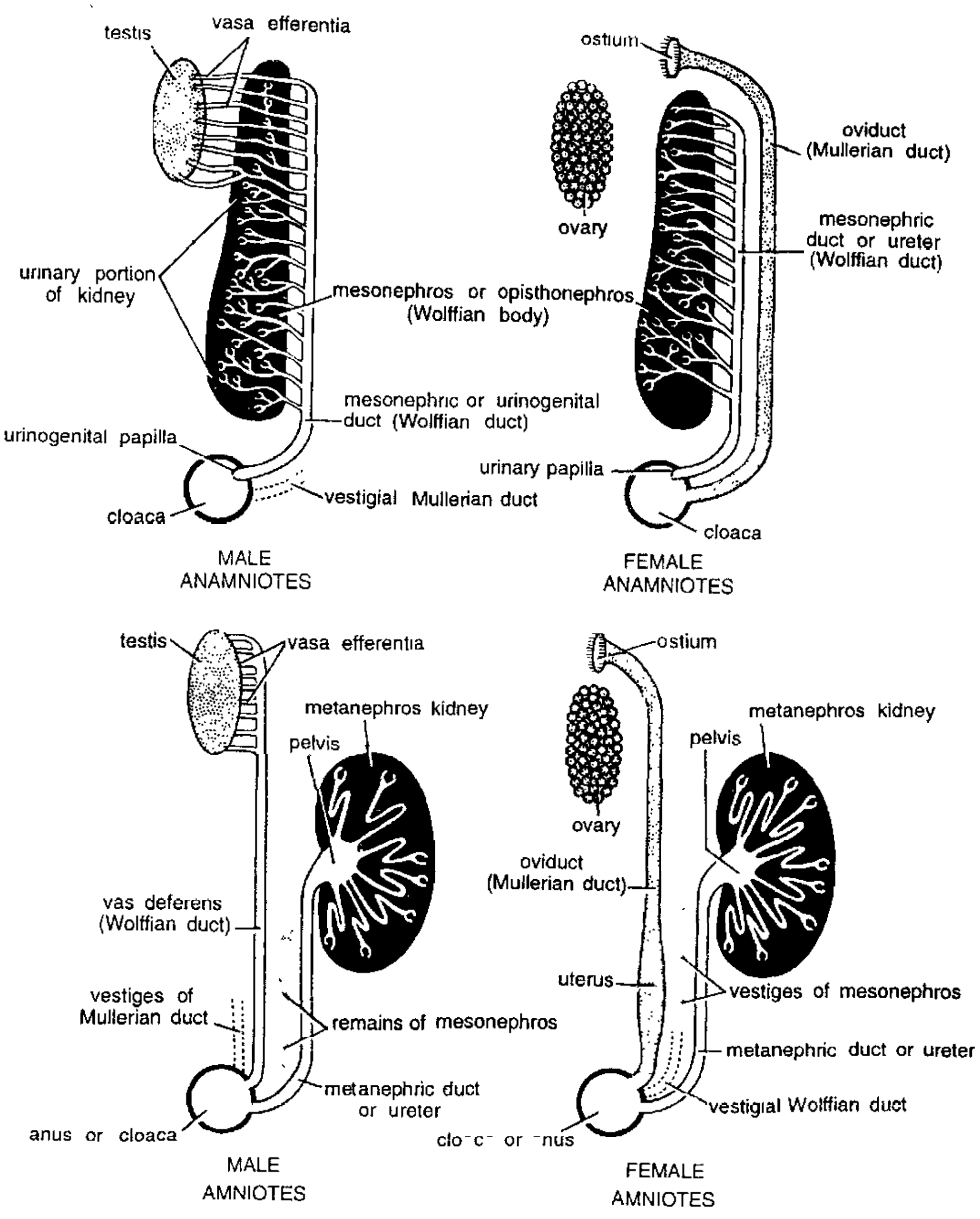

Fig 6. Schematic representation of evolution of urinogenital organs and their ducts in vertebrates

sterile. Gonads remain suspended in coelom from dorsal bodywall by a fold of dorsal mesentery, called ***mesorchium*** in males and ***mesovarium*** in females. Generally, one pair of gonads is present. But, some vertebrates have a single gonad only because of either fusion of both embryonic genital ridges (most cyclostomes, perch and some other fishes), or degeneration of one juvenile gonad (hagfishes, some elasmobranchs and lizards, alligators and most birds). Associated with the gonads are special gonoducts or genital ducts, *vasa deferentia* in males and *oviducts* in females, to transport gametes to cloaca or to outside body. However, cyclostomes and a few elasmobranchs lack genital ducts. Their eggs and sperm escape body cavity via abdominal pores.

1. Testes and male genital ducts. Testes of vertebrates are paired organs of moderate size, usually found attached to kidneys. Each testis is a compact gland, covered by coelomic epithelium and composed of numerous highly coiled *seminiferous tubules* embedded in connective tissue. Tubules are lined by germinal epithelium which gives rise to billions of sperm. On maturity the sperm are set free in the lumen of tubules and move towards the genital ducts.

Some *Cyclostomes* have a single median testis without a genital duct. Sperms are released in the coelom from where they pass through *abdominal pore,* located at posterior part of coelom. In dogfish, the two testes are elongated bodies. In most *anamniotes,* the opisthonephros (or mesonephros) is differentiated into anterior genital and posterior renal portions. In the anterior genital portion in males, some uriniferous tubules lose excretory function, form slender *vasa efferentia,* and become continuous with seminiferous tubules of the adjacent testis. They serve to convey sperm of testis to the mesonephric duct of kidney. Thus, in male anamniotes, mesonephric or wolffian duct forms a *urinogenital duct,* serving both as a vas deferens for sperm as well as a ureter for urine. However, in many elasmobranchs (e.g. dogfish), accessory urinary ducts drain urine from kidney to cloaca so that the mesonephric duct serves entirely or mainly as a vas deferens. The anterior genital part of kidney along with the part of mesonephric duct forms an *epididymis.*

In the embryos of *Anura,* each testis is made of two portions. In male frog, the anterior portion disappear and the posterior portion becomes the adult functional testis. In adult male toad, the anterior portion also persists as the *Bidder's organ,* containing large cells similar to immature ova.

In male *amniotes,* a metanephros develops as the adult functional kidney with its own urinary duct or *ureter* to transport urine. Thus, mesonephric or Wolffian duct becomes solely a genital duct or *vas deferens.* The remnants of embryonic mesonephros and a coiled portion of mesonephric duct become the *epididymis* of the adult kidney. From each testis sperms pass first through epididymis, then through vas deferens to reach urethra.

In most mammals testes descend permanently into extra-abdominal skin bags called *scrotal sacs.* In rabbits, bats and rodents, they are lowered into sacs and retracted at will. Passage between abdominal cavity and scrotal sac, through which testis descends, is called *inguinal canal.* However some mammals such as monotremes, insectivores, elephants, whales, etc., lack scrotal sacs so that their testes remain permanently intra-abdominal like ovaries.

2. Copulatory organs. Copulatory organs are absent in anamniotes, since they have usually external fertilization. But, in amniotes, fertilization is internal, and preceded by copulation or mating. Male amniotes usually develop *intromittant* or *copulatory organs* for transferring sperm into the genital tract of females, during copulation. They are particularly characteristic of reptiles and mammals.

In elasmobranchs (e.g. dogfish), bases of pelvic fins are modified as intromittant organs called *claspers.* These are grooved, cylindrical structures that are inserted into the female cloaca to inject sperm. In dog fishes and some allied forms there is blind muscular sac called *siphon,* located at the base of claspers. This sac gets filled with sea water which is used to force the spermatic fluid into the cloacae of female. In several teleosts, the anal fin is modified as a *gonopodium* for sperm transport. It is modification of anal fin. Snakes and lizards have a pair of retractile, grooved and sac-like *hemipenes* which can be everted through cloaca. Their retraction is controlled by modified body wall musculature. Turtles, crocodilians, some birds (drakes, ganders, ostriches) and prototherian mammals have an unpaired, grooved and erectile *penis* formed as a thickening of cloacal floor. Only higher mammals have a true external, erectile penis with a tubular groove continuous with a spongy urethra. A series of *accessory sex glands* associated with penis secrete a fluid in which sperm are carried.

3. Ovaries and female genital ducts. In female anamniotes, ovaries are large, occupying much of the body cavity and produce thousands of eggs as fertilization is external. In amniotes, ovaries produce fewer eggs because fertilization is internal. Ovaries of reptiles and birds are still large and the eggs produced contain much yolk. However, mammalian eggs contain very little yolk so that their ovaries also remain quite small.

Ovaries are generally paired structures, but only a single median ovary occurs in cyclostomes, as also in some teleosts (e.g. perch). They are not attached to kidneys like testes in the males. Only the right ovary is functional in many elasmobranchs, whereas only the left ovary becomes mature in birds and some primitive mammals (e.g. *Ornithorhynchus*).

Histologically, an ovary is a mass of connective tissue with an outer layer of germinal epithelium showing ova in various stages of development. Ovaries are hollow and saccular in fishes and amphibians but compact in amniotes, especially in mammals, in which each ovum is surrounded by a follicle. Mature eggs are released either internally into the central ovarian cavity (teleosts) which is continuous with the lumen of the oviduct, or extruded externally into the surrounding coelom or bodycavity (Tetrapoda). This process is termed *ovulation*.

In all vertebrate embryos, except cyclostomes, the coelomic epithelium on the outside of mesonephric duct develops a groove which becomes closed to form a tube called *Mullerian duct*. In adult males, Mullerian duct becomes vestigial and functionless. In adult females, it grows larger and becomes the female genital duct or *oviduct*. It opens anteriorly into coelom, in the region of degenerating pronephros, by a *coelomic funnel* or *ostium*, and terminates posteriorly into cloaca. In female elasmobranchs, the Mullerian duct is formed differently by the longitudinal splitting of the pronephric duct. Thus, in adult female anamniotes, both the Mullerian duct (oviduct) and the Wolffian duct (mesonephric or urinary duct) are present. But, in adult female amniotes, with the development of adult metanephros and its metanephric duct or ureter, mesonephros and its duct (Wolffian duct) degenerate leaving only vestiges known as *provarium*.

In viviparous mammals, posterior ends of both the Mullerian ducts become fused and are modified into a *uterus* in which the embryos develop, and a *vagina* which receives the male intromittant organ during copulation. The remaining anterior parts or oviducts are relatively short, narrow and convoluted and called the *fallopian tubes*. Condition of uteri varies in different mammals. When uteri remain double without fusion, it is called *duplex uterus* (marsupials). When uteri partially fuse so as to form two horns and two separate lumens inside, it is called *bipartite uterus* (hamster, rabbit). When there are two horns but a single internal cavity it is termed *bicornuate uterus* (ungulates). When uterine horns are absent and both uteri fuse completely with a single internal cavity, it is termed *simplex uterus* (Primates, some bats, armadillos).

IMPORTANT QUESTIONS

» ***Long Answer Type Questions***

1. Give general account of evolution of kidney in vertebrate series.
2 Trace the fate of pro-, meso-, and metanephros in vertebrates.
3. Describe the evolution of genital ducts in different vertebrates

» *Short Answer Type Questions*

1. Write short notes on — (i) Archinephros, (ii) Mesonephros, (iii) Metanephros, (iv) Mullerian duct, (v) Nephron, (vi) Opisthonephros, (vii) Pronephros, (viii) renal corpuscle.

» *Multiple Choice Questions*

1. Functional unit of kidney :
   (a) Nephron (b) Neuron
   (c) Renal corpuscle (d) Glomeruli
2. Hypothetical primitive kidney :
   (a) Archinephros (b) Pronephros
   (c) Nephron (d) Mesonephron
3. Archinephros is found in :
   (a) Fishes (b) Reptiles
   (c) Larval cyclostomes (d) Amphibians
4. Wolffian body :
   (a) Archinephros (b) Pronephros
   (c) Mesonephros (d) Metanephros
5. Urinary bladder opens to exterior through :
   (a) Ureter (b) Urethera
   (c) Pelvis (d) Tubule
6. The functional adult gonad is derived from which part of genital ridge :
   (a) Gonal (b) Pregonal
   (c) Epigonal (d) Endogonal
7. In mammals testes are found in :
   (a) Peyer's patches (b) Bidder's organ
   (c) Inguinal canal (d) Scrotal canal
8. Oviduct in vertebrates is modified :
   (a) Wolffian duct (b) Mullerian duct
   (c) Inguinal canal (d) Urinary duct

ANSWERS

1. (a) 2. (a) 3. (c) 4. (c) 5. (b) 6. (a) 7. (d) 8. (b).

57

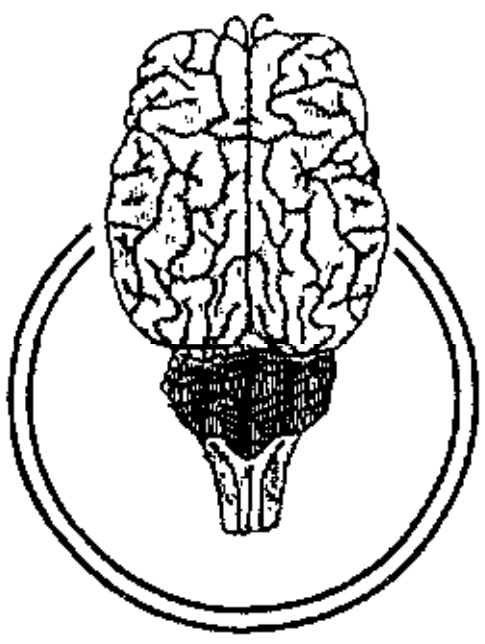

Nervous System in Vertebrates

Nervous System and its Functions

In all the multicellular animals above the level of sponges, the system meant to perceive stimuli detected by the receptors, to transmit these to various body parts, and to effect responses through effectors, is called *nervous system*. In vertebrates, it is highly specialized and plays at least three vital roles :

1. **Response to stimuli.** By responding to all sorts of stimuli, it acquaints the organism with them so that the organism may react and orient itself favourably in the surrounding environment.

2. **Coordination.** Along with endocrine system, the nervous system also serves to coordinate and integrate the activities of various parts of the body so that they act harmoniously as a unit. This makes possible the integrated control of the internal body environment *(homeostasis)*. However, the nervous system brings about rapid coordination by means of nerves, whereas the endocrine system does so gradually and slowly by secreting hormones into blood.

3. **Learning.** By accumulating memories from past experiences, in higher vertebrates at least, the nervous system serves as a centre for learning.

The branch of medical science dealing with the structure (anatomy), functions (physiology) and diseases (pathology) of nervous system is called *neurology*.

Division of Nervous System

For convenience of study, the nervous system is divided into three parts :

1. **Central nervous system or CNS.** It consists of the *brain* and *spinal cord*. It coordinates the impulses received from receptors and transmitted to the effectors for response.

2. **Peripheral nervous system.** It is composed of 10 or 12 pairs of *cranial nerves* coming from brain and several pairs of *spinal nerves* from the spinal cord. It provides the connecting link or living lines of communication between the receptors, the central nervous system, and the effectors.

3. Autonomic nervous system. It innervates smooth and cardiac muscles and glands. It is concerned with the involuntary or automatic body activities, such as the peristalsis of the alimentary canal and the beating of the heart. Autonomic system is [illegible] a part [illegible] peripheral system as the two are connected together.

Anatomy of Nervous System : The Neuron

The nervous system is composed of nerve cells or *neurons*, surrounded by a delicate web of connective tissue called *neuroglia* (Fig. 1). Neuron or neurone is the structural as well as functional unit of nervous system. According to the 'neuron theory', each neuron is a distinct anatomical unit, having no protoplasmic continuity with other neurons. It is also physiologically distinct, so that damage or destruction of a neuron may not affect adjacent neurons. The neuron, rather than the nerve, transmits the nerve impulse.

[I] Structure of a neuron

Neurons are of different shapes, but each consists of an irregular cytoplasmic cell body called *cyton*, with a number of branching cell *processes* or *fibres*.

1. Cyton. Cyton contains a nucleus and several small basophilic *Nissel granules* or *tigroid bodies* that readily stain with methylene blue. These granules are made of ribonucleic acid (RNA) and take part in protein synthesis. Cytoplasm of cyton also contains a network of fine, thread-like *neurofibrillae*. A group or mass of cell bodies within the gray matter of brain or spinal cord is called a *nucleus*, while outside the central nervous system it is called a *ganglion*.

2. Nerve fibres. Two types of fibres are differentiated on the basis of the direction of nerve impulse conducted by them.

(a) Dendrites. These are shorter, usually several, much branched, with Nissl granules, and carry impulses towards or into the cell body.

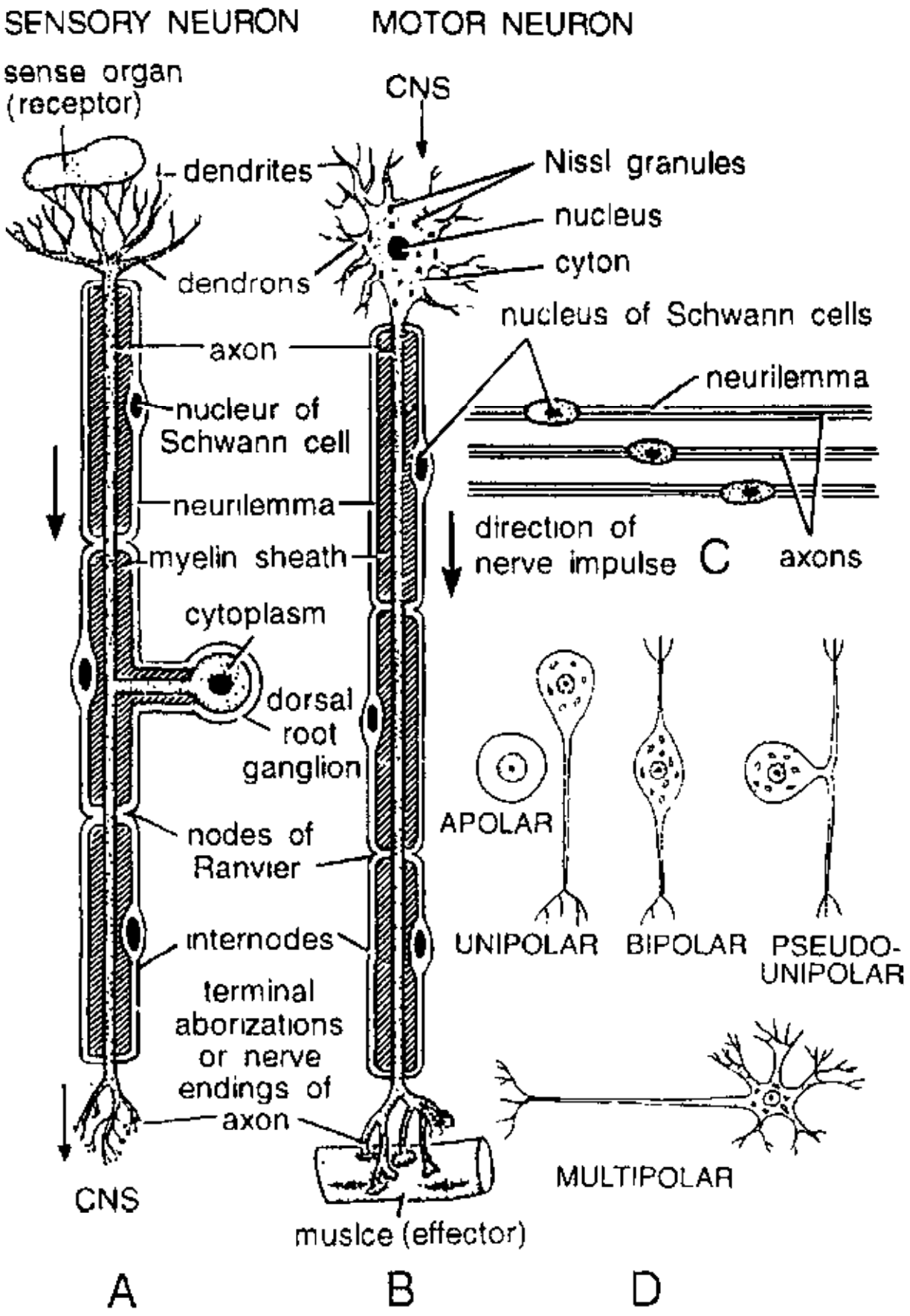

Fig. 1 Structure of neurons and nerve fibres. A—Sensory neuron. B—Motor neuron C—Non-medullated nerve fibres. D—Kinds of neurons.

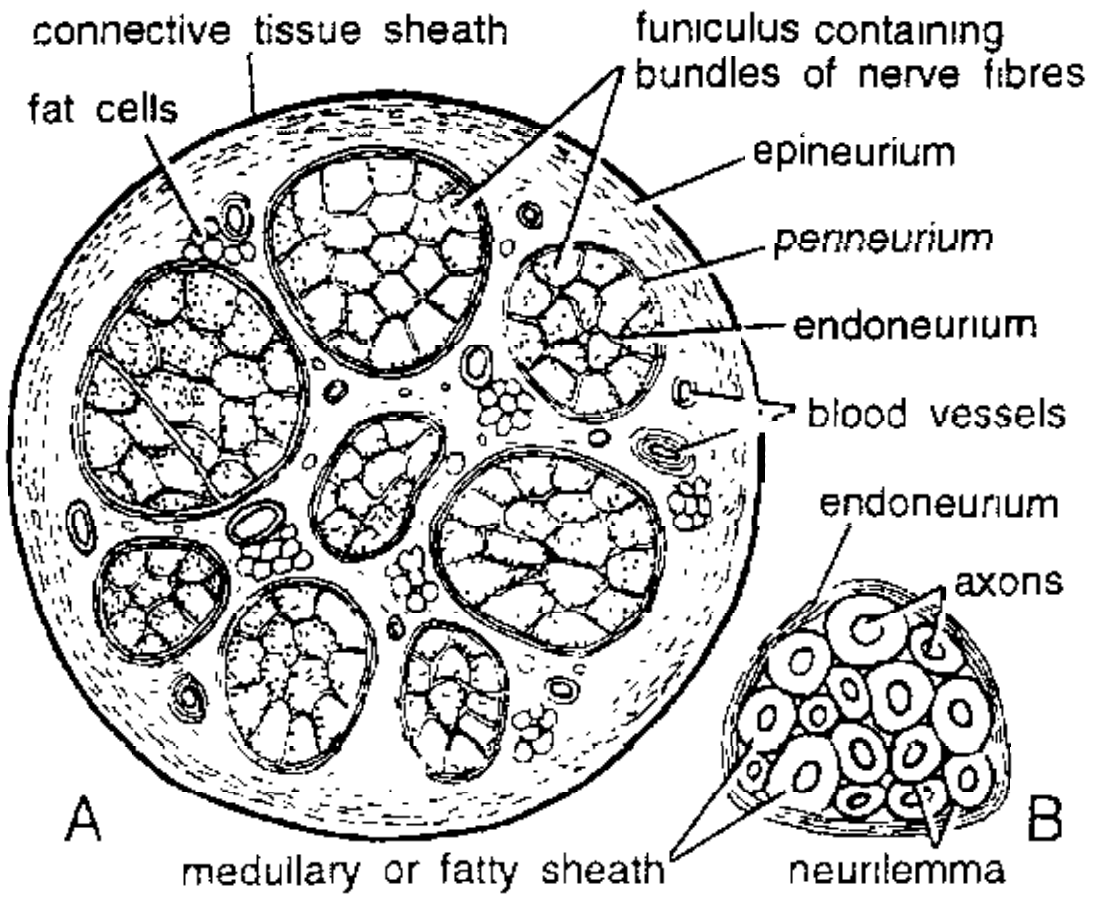

Fig 2 Structure of a nerve A—Nerve in T S B—A bundle of nerve fibres in T.S

(b) Axon. It is longer, usually single, without branches and Nissel granules, and normally conducts impulses away from the cell body.

A nerve fibre (Fig. 2) consists of a central thin cytoplasmic strand, called *axis cylinder*, which is continuous with the cell body. All nerve fibres outside brain and spinal cord, are covered by a thin delicate membrane, the *Schwan sheath* or *neurilemma*. In most long nerve fibres, there is a layer of lipoid or fatty material, called *myelin* or *medullary sheath*, between axis cylinder and neurilemma. Such fibres are termed *myelinated* or *medullated* and appear white. Myelin substance is not continuous uniformly but becomes interrupted at intervals by circular constrictions termed *nodes of Ranvier*. Part of nerve fibres between two adjacent nodes is called an *internode*. Nerve fibres which lack the fatty sheath are called *non-myelinated* or *non-medullated* and are gray in appearance.

Just below neurilemma is a thin cytoplasmic layer with scattered flat nuclei, forming *sheath cells* or *Schwann cells*. They secrete the myelin sheath and neurilemma. Each internode is covered usually by a single Schwann cell. *Collateral branches* may arise at right angles from long fibres or axons.

3. Synapses. Neurons form pathways for conduction of nerve impulses, but cytoplasm of one neuron is not continuous with that of another. Electron microscope has shown that branches of an axon end in *terminal buttons* full of mitochondria. These lie in close proximity but without actual organic connection with terminal branches of a dendrite of another neuron. The small gap thus left between the juxtaposed processes is called a *synapse* or *synapsis*. Only the branches of an axon form a synapse with the dendrites of another neuron. The whole nervous system in fact represents chains of neurons linked together by synapses in a complicated web.

[II] Kinds of neurons and fibres

Nerve fibres and neurons are comparable to a 'one-way-traffic' system, conducting nerve impulses in one direction only. Functionally, the following main types of nerve fibres and neurons are found :

1. Afferent or sensory. These transmit and carry impulses from a receptor to the central nervous system.

2. Efferent or motor. These transmit and carry impulses from the central nervous system to the various effector organs.

3. Association or adjustor neurons. These lie within the brain or spinal cord and link together through synapses the afferent and efferent neurons. Neurones are commonly classfied according to the number of processes.

(i) Apolar neurones. They have no processes.

(ii) Unipolar neurones. All developing neuroblasts pass through a stage when they have only one process the axon. In the adult such unipolar neurons are not commonly seen.

(iii) Bipolar neurones. These neurones are spindle shaped possessing an axon at one pole and a dendron at the other end. In the adult they are found in retina.

[III] Nerve

A nerve consists of numerous nerve fibres (axons or dendrites), outside the central nervous system, bound together in smaller bundles, like wires in a cable, by white connective tissue layers called *perineurium*. Surrounding tissue includes blood vessels to supply nutrients and oxygen. The external coat of fibrous connective tissue of nerve is termed *epineurium*.

Nature of Nerve Impulse

The nature of nerve impulses passing along a nerve fibre is partly physical and partly chemical (Fig. 3). A wave of electric change or disturbance accompanies the nerve impulse. This electric charge, known as the *action current*, can be recorded with a galvanometer. While transmitting an impulse, the nerve consumes more O_2, produces more CO_2 and generates a minute but measurable amount of heat, than a resting nerve. These factors clearly indicate the physico-chemical nature of the nerve impulse.

The synapse has a *polarity*, that is, like a 'physiological valve', it allows an impulse to travel in one direction only, from axon of one neuron to the dendrite of other. In fact, an impulse does not travel through a synapse, but a fresh impulse is induced on its other side. On reaching the terminal buttons of an axon, the impulse induces them to produce a small amount of a chemical terminations neurotransmitter, therefore, all synapses are called cholinergic. Acetyl choline is highly unstable as it is readily neutralized by an enzyme acetyl cholinesterase out one process *h* splits into processes. One these processes is to the phery and the *r* goes to the tral nervous item. Such cells are found in all final ganglia. Utipolar neurones. These cells have a number of dendrones and an axon. They have various shapes depending mainly on the number and position of the endrones, usually *acetylcholine*, which sets up a fresh impulse in the next neuron. On the other hand, terminations of sympathetic fibres release *sympathin*, a substance like adrenalin, and which is antagonistic to acetylcholine. These neuro-hormones may continue to stimulate the other neuron, but they are quickly inactivated by an enzyme, *cholinesterase*.

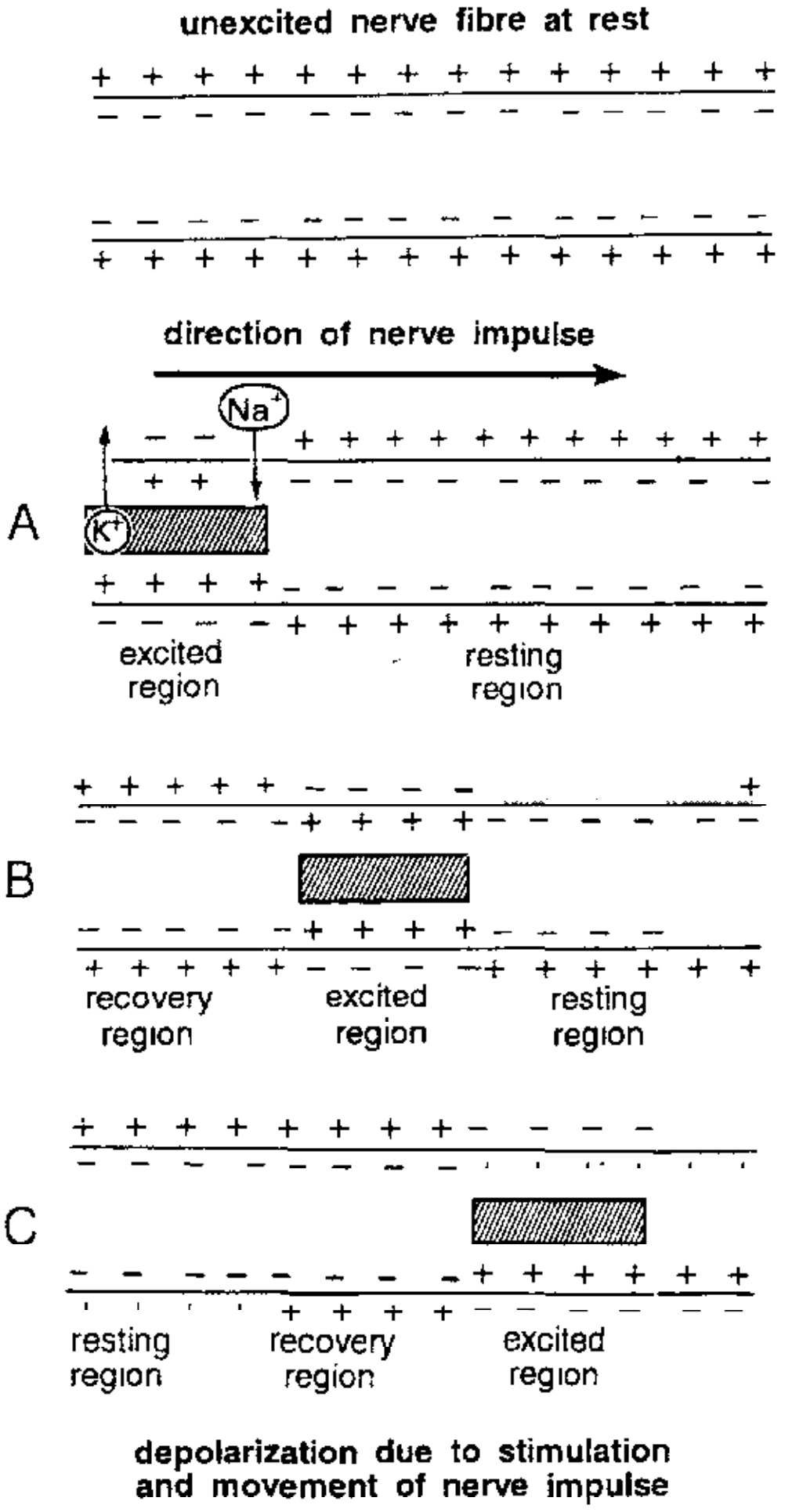

Fig. 3. Diagrammatic representation of electrical conduction of impulses along a nerve fibre

A neuron is able to transmit an electric impulse very rapidly, at a speed of 100 metres per second in man. Medullated fibres conduct impulses much faster than the non-medullated fibres. It travels at a uniform speed with the same intensity for a long time and does not spread to adjacent tissues due to insulation provided by myelin sheaths. A refractive period usually occurs when the depolarized nerve fibre cannot carry another stimulus. It is believed that the nerves are never tired. Impulses are conducted on the basis of 'all or none' principle.

Development of Central Nervous System

The central nervous system of vertebrates includes the *brain* and the *spinal cord*. These are derived from a longitudinal, mid-dorsal ectodermal

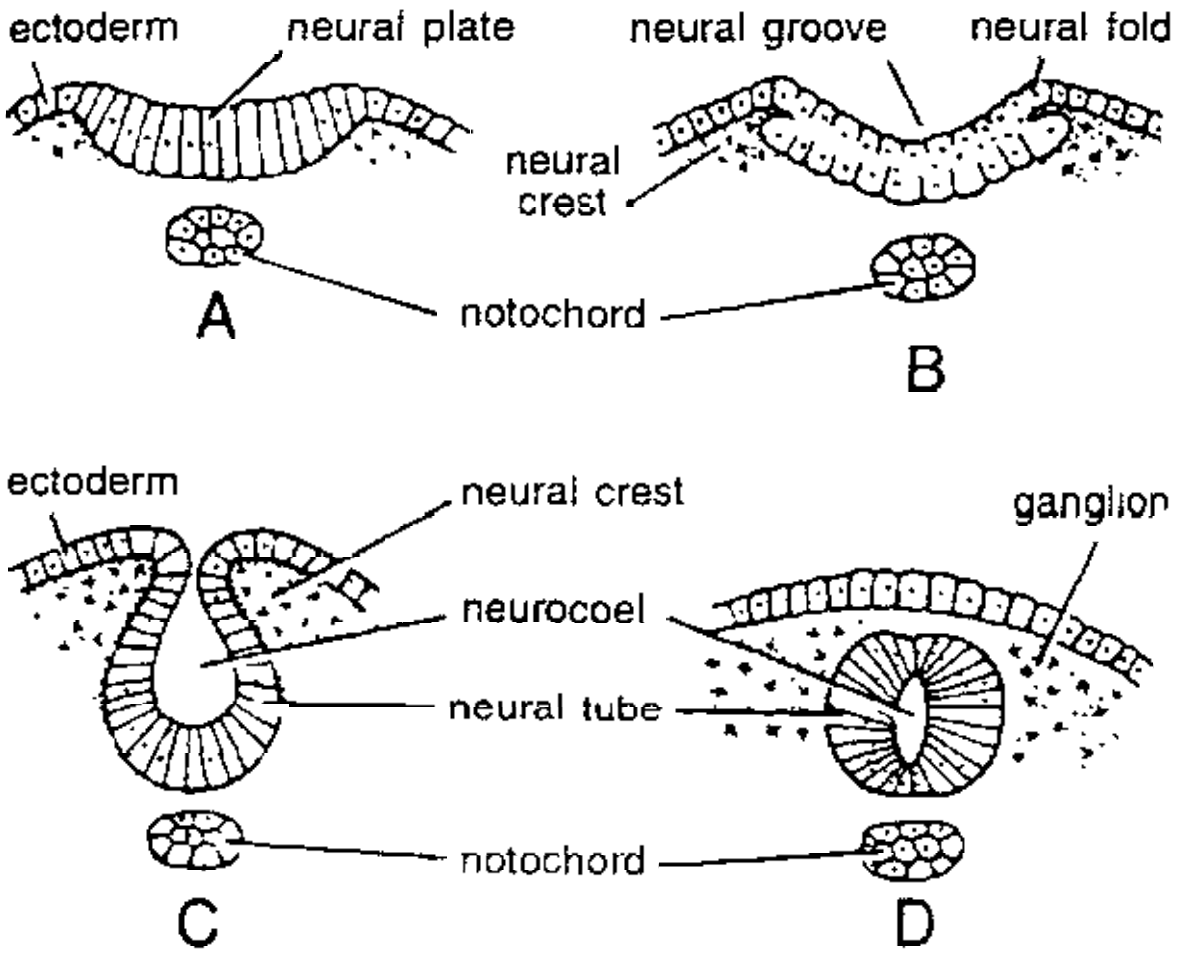

Fig. 4. Stages in the embryonic development of central nervous system in T.S.

thickening of the embryo, called the *medullary* or *neural plate* (Fig. 4). This neural plate or neural groove is converted by fusion into a closed mid-dorsal longitudinal *neural tube,* lying above the notochord. The fusion of neural fold is not complete along the entire length of neural groove. A small opening the *neuropore* is left out at the anterior end which communicates to exterior. The neuropore persists for a while and finally closes. Moreover it may not be present in all the cases. Posteriorly, the neural tube may communicate temporarily with the archenteron by the *neurenteric canal.* The neural tube is wide anteriorly because anterior part of neural plate is wider than posterior and this wider part forms the brain. Histologically, the embryonic neural tube exhibits three zones of cells :

1. Germinal layer. These are actively dividing cells, lining the neural canal. They form the connective tissue lining of neural canal, called *ependyma,* and also proliferate into mantle layer cells.

2. Mantle layer. It consists of embryonic neurons or *nematoblasts*, forming the gray matter.

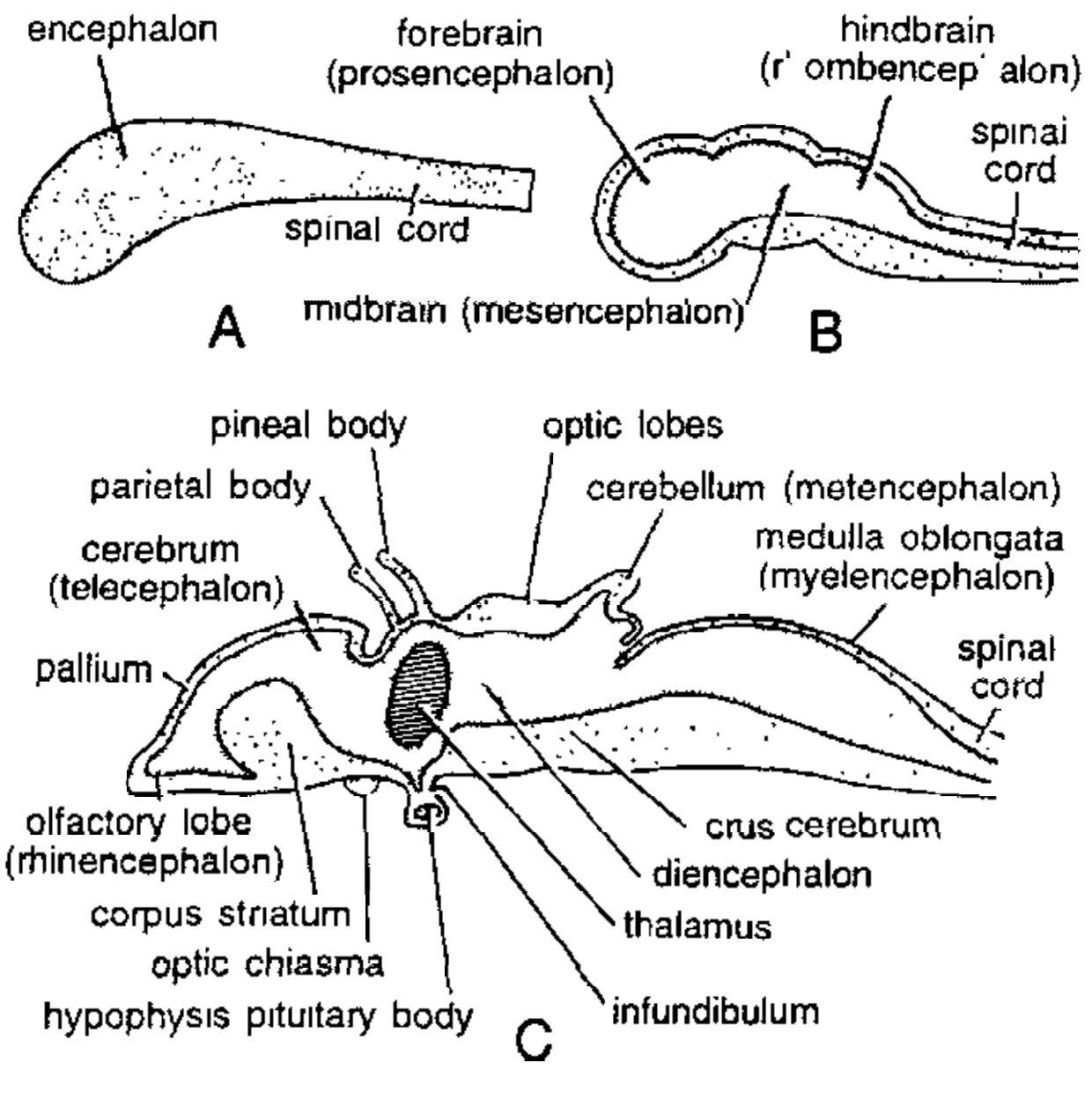

Fig 5 Stages in development of brain. A—Anterior end of neural tube in lateral view. B—M L.S. of embryonic brain to show three primary cerebral vesicles. C—Differentiation of brain from three vesicles.

3. Marginal layer. It consists of nerve fibres, mostly surrounded by fatty myelin sheaths, and forms the *white matter.* Neurons and fibres are supported by a special connective tissue of ectodermal origin, the *neuroglia,* cells of which become increasingly abundant and diversified in higher vertebrates.

Development of brain. The anterior end of embryonic neural tube is already enlarged forming the embryonic brain (Fig. 5), called *encephalon.* By differential growth and two constrictions, it is divided into a linear series of three *primary cerebral vesicles*, termed the *forebrain, midbrain* and *hindbrain.* These give rise to the three major divisions of the adult brain— (i) *prosencephalon* (forebrain), (ii) *mesencephalon* (midbrain), and (iii) *rhombencephalon* (hindbrain). These further become subdivided into 5 subdivisions. The various parts of the adult brain in different vertebrates are formed by modifications, that is, by thickenings and foldings of these 5 subdivisions. The adult brain has a series of cavities, called *ventricles,* which are in continuation with the central canal of the spinal cord and filled with a cerebro-spinal fluid.

The various usual parts with prominent associated structures of a vertebrate brain have been shown in Fig. 6 and listed in the Table 1.

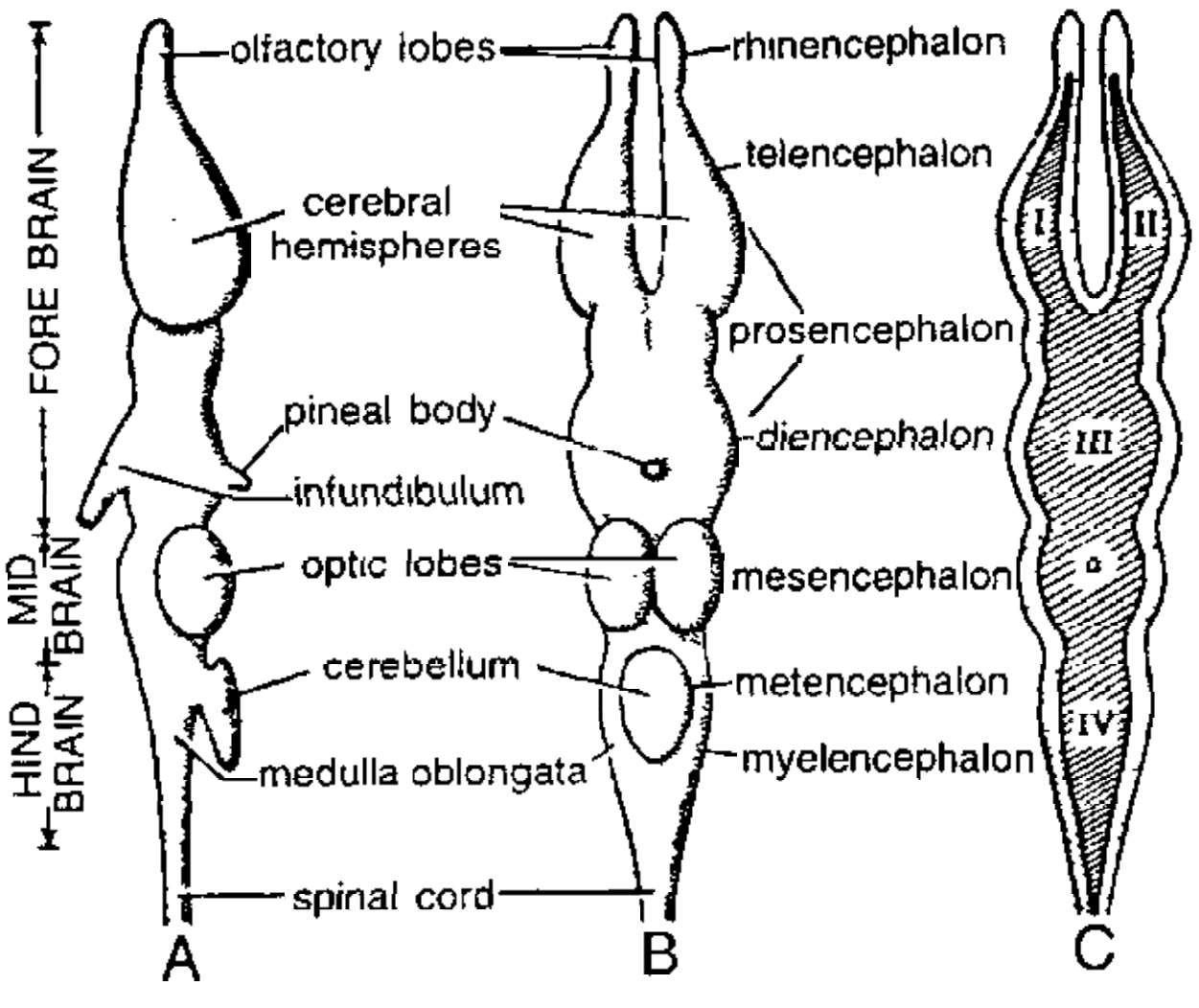

Fig. 6. Pattern of generalized vertebrate brain A—Lateral view B—Dorsal surface C—H L.S. showing ventricles.

Table 1. **Subdivisions, Parts and Associated Structures of a Vertebrate Brain.**

Divisions	Subdivisions	Parts	Cavity	Associated Structures
I. PROSEN-CEPHALON (Forebrain)	**1. Telencephalon**	Rinencephalon	I Ventricle *(Rhinocoel)*	Olfactory bulbs Olfactory tracts Olfactory lobes Palaeocortex on pallium
		Cerebral hemispheres	II or Lateral Ventricles *(Paracoels)* ↓ Formen of Monro	Corpora striata or basal ganglia Corpus callosum Neocortex on pallium Paraphysis
	2. Diencephalon	Epithalamus (roof)	↓ III Ventricle *(Diacoel)*	Habenulae Pineal apparatus Parapineal or parietal
		Thalamus (sides)		
		Hypothalamus (floor)		Hypothalmic nuclei Optic chiasma Median eminence Infundibular stalk Pituitary Saccus vasculosus Mamillary bodies Anterior choroid plexus
II. MESSEN-CEPHALON (Midbrain)	—	Crura cerebri (floor)	*Iter* or *cerebral aqueduct*	Optic lobes] Tectum Auditory lobes] Cerebral peduncles
III. RHOMBEN-CEPHALON (HINDBRAIN)	**1. Metencephalon**	Cerebellum		Trapezoid body Pons
	2. Myelecephalon	Medulla oblongata	IV Ventricle *(Metacoel)*	Restiform bodies Pyramids

Comparative Account of Brain in Vertebrates

Brain of all vertebrates, from fish to man, is built in accordance with the same basic architectural plan (Figs. 6–8). However, form of brain differs in different vertebrates in accordance with the habits and behaviour of the animals.

1. Cephalochordates. In amphioxus, brain does not consist of forebrain, midbrain and hindbrain. Instead, the so-called brain is made of an anterior *prosencephalon* or *cerebral vesicle* with a single enlarged ventricle. It is lined with cilia and long filamentous processes of ependymal cells as revealed by electron microscope. Anterior extension of notochord may suggest absence of a forebrain.

2. Cyclostomes. Brain is very primitive. Subdivisions are not well marked. Two olfactory lobes are prominent, but cerebral hemispheres are quite small. Cavities of cerebral hemispheres or lateral ventricles are rudimentary. Pineal apparatus and parapineal (=parietal) body are very well developed in *Petromyzon*, though they are vestigial in *Eptatretus (=Bdellostoma)* and absent in *Myxine*. Connected to pineal apparatus is epithalamus made of two *habinulae ganglia*. The two optic lobes are imperfectly differentiated. Medulla oblongata is very well developed while cerebellum is a small transverse dorsal band. A well defined infundibulum from hypothalamus of diencephalon bears a hypophysis or pituitary body.

3. Fishes. Brain of fishes is more advanced than that of cyclostomes. However, subdivisions of brain are seen in their primitive relations.

(a) Elasmobranchs. In elasmobranch fishes (shark or dogfish), olfactory organs are enormous

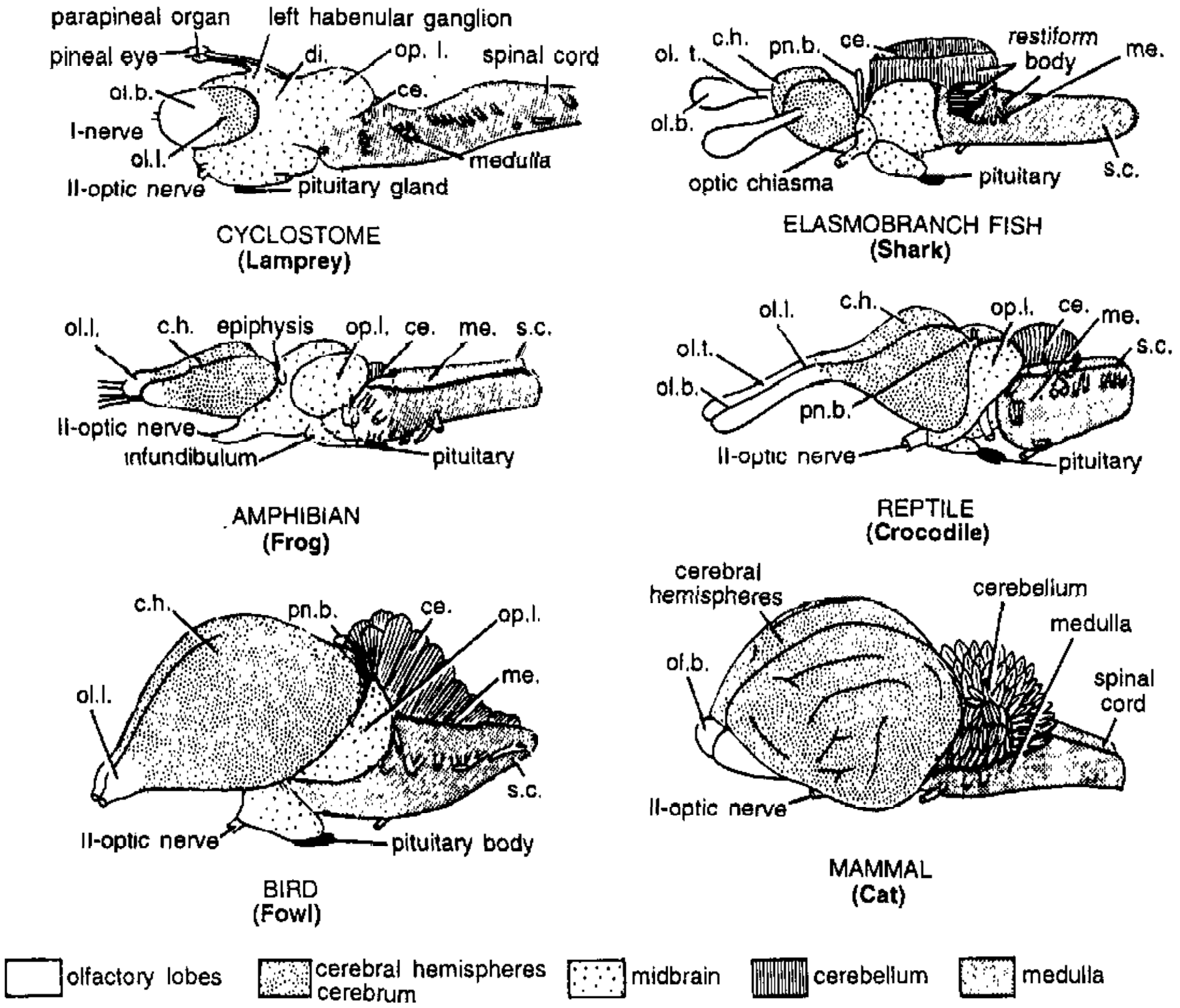

Fig. 7. Brains of representative vertebrates in lateral view. ce.—cerebellum. c.h.—cerebral hemisphere. di.—diencephalon. inf. —infundibulum. m.—medulla oblongata. ol.b.—olfactory bulb. ol.l.—olfactory lobe. ol.t.—olfactory tract. op.l.—optic lobe. pi.—pituitary. pn.b.—pineal body. s.c.—spinal cord.

so that olfactory lobes of brain are correspondingly large, attached to cerebrum by short but stout olfactory tracts or peduncles. Optic lobes and pallium are relatively moderate in size. Midbrain cavity (III ventricle) is quite large and extends into optic lobes. A thin-walled vascular sensory organ, called *saccus vasculosus*, is attached to pituitary and connected by fibre-tracts with cerebellum. Pineal apparatus is well developed. Topographical features of hindbrain are least pronounced. Cerebellum is especially large due to active swimming habit. To assist cerebellum in the maintenance of equilibrium, ruffle-like *restiform bodies* are present at the antero-lateral angles of medulla.

(b) Osteichthyes. In bony fishes, brain is more specialized than in elasmobranchs. In perch, olfactory lobes, cerebral hemispheres and diencephalon are smaller while optic lobes and cerebellum larger than in a shark. Some bony fishes have *restiform bodies*. In bottom-feeders, having scattered taste buds on body surface, the antero-lateral sides of medulla show unusual bulgings or *vagal lobes*. Parapineal body is absent in modern teleosts.

4. Amphibians. Brain of frog shows many contrasts from that of dogfish. Smaller olfactory lobes and larger optic lobes indicate a greater reliance on sight rather than smell. *Corpus striatum* or *paleostriatum* (floor of cerebrum)

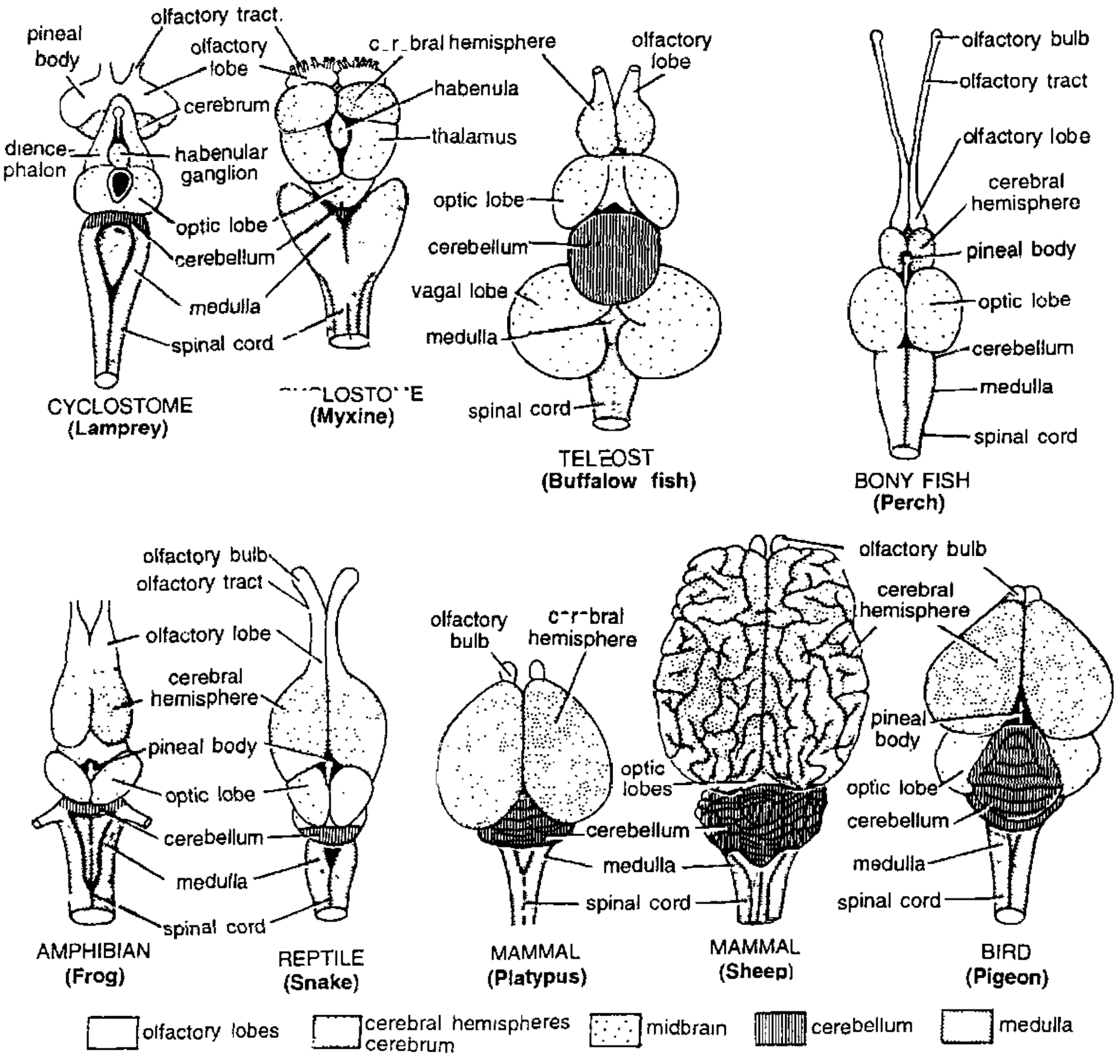

Fig 8 Brains of representative vertebrates in dorsal veiw.

receives greater number of sensory fibres projected forward from thalamus than in fishes. Two cerebral hemispheres show greater development in accordance with more complex activities of locomotion, hibernation, breeding, etc. However, optic lobes are probably the dominant coordinating centres in amphibian brain. The walls of mid brain are thickened and reduce the lumen into a narrow passage called, *aqueduct*. Poor development of cerebellum, a mere transverse band, shows relative decrease in muscular activity. Medulla is also small. A small pineal body is present in all the modern amphibians.

5. **Reptilians.** Reptilians brain shows advancement in size and proportions over that of amphibians because of complete terrestrial mode of life. Telencephalon increases to become the largest region of brain. Two long olfactory lobes are connected to cerebral hemispheres which are larger than in amphibians because of greater thickness and enlargement of corpora striata. A fine *vomeronasal nerve* from the organ of Jacobson goes to the olfactory bulbs. Parapineal body, more often called the *parietal eye*, is still found in *Sphenodon* and some modern lizards, but is vestigial or absent in other reptiles. A pair of

auditory lobes are found posterior to optic lobes which are not hollow. The III ventricle is reduced to a narrow *cerebral aqueduct.* Cerebellum is somewhat pear-shaped and larger than in amphibians.

6. Birds. Avian brain is proportionately larger than that of a reptile, and is short and broad. Olfactory lobes are small due to poor sense of smell. Two cerebral hemispheres are larger, smooth and project posteriorly over the diencephalon to meet the cerebellum. Pallium is thin but corpus striatum is greatly enlarged making lateral ventricle small and vertical. Third ventricle is also narrow due to great development of thalami. Optic lobes on mid-brain are conspicuously developed in correlation with keen sight, but they are somewhat laterally displaced. The cerebellum is greatly enlarged with several superficial folds (flocculi) due to many activities involving muscular coordination and equilibrium such as flight and perching.

7. Mammals. Parts of vertebrates brain in linear arrangement become progressively enlarged from fishes onwards until they reach their peak in mammals. Brain is proportionately larger than in other vertebrates. *Cerebral hemispheres* of Prototheria are smaller and smooth, like those of reptiles. They are larger but smooth in Metatheria. In most higher mammals (Eutheria), cerebral hemispheres become greatly enlarged and divided into lobes, with thick cerebral cortex of gray matter. In mammals such as rabbit, the surface of cerebral hemispheres is relatively smooth with few fissures. In others, such as man and sheep, surface is immensely convoluted with a number of elevations *(gyri)* separated by furrows *(sulci).* This folding increases the surface cortex or gray matter containing nerve cells, resulting in greater intelligence without adding to the size of brain. The two hemispheres are joined internally by a transverse band of fibres, the *corpus callosum,* not found in other vertebrates or even in Prototheria and Matatheria.

Olfactory lobes are relatively small but clearly defined and covered by the hemispheres. Diencephalon and midbrain are also completely covered by the cerebral hemispheres. Characteristic of mammals are 4 almost solid optic lobes, called *corpora quadrigemina,* on the roof of midbrain. The III ventricle or *iter* of midbrain is a laterally compressed vertical passage, called *cerebral aqueduct.*

Cerebellum is also large, conspicuously folded and may overlie both midbrain and medulla. Usual folds are a median *vermis,* two lateral *flocculi* and their mushroom - like projections, the *paraflocculi.* The other chief topographical features of mammalian hindbrain include the *pyramids* carrying voluntary motor impulses from higher centres, the *pons varoli* with crossing or decussating fibres connecting opposite sides of cerebrum and cerebellum, and the *trapezoid* body of transverse fibres relaying impulses for sound. Hindbrain contains centres for the regulation of digestion, respiration and circulation.

Cranial Nerves

The peripheral nervous system includes *cranial* and *spinal nerves.* All the nerves arise in pairs. Cranial nerves have both afferent and efferent fibers, arise from brain and emerge through skull foramina. There are 10 pairs of cranial nerves in anamniotes (cyclostomes, fishes, amphibians) and 12 pairs in amniotes (reptiles, birds, mammals). Their sequence and distribution is essentially the same in all vertebrates. Table 2 provides a summary of the serial number, names, origin from brain, distribution, nature and functions of cranial nerves in vertebrates.

Terminal nerves. An additional pair of anterior-most terminal nerves are found in all vertebrates including man. They emerge from rhinencephalon close to olfactory roots through neuropore of cerebrum. They are numbered zero (0) because of their discovery after all other cranial nerves were already numbered.

Autonomic Nervous System

Cranial and spinal nerves (*somatic nerves*) mainly innervate the skeletal or voluntary muscles and direct the adjustment of the vertebrate to its surroundings. On the other hand, *autonomic nerves*

***Table* 2. Cranial Nerves (paired) of Vertebrates.**

	Name	Origin	Distribution	Nature	Functions
I.	**Olfactory**	Olfactory lobe or bulb	Olfactory epithelium in nasal cavity	*Sensory*	Smell
II.	**Optic**	Optic lobe on midbrain	Retina of eye	*Sensory*	Sight
III.	**Oculomotor**	Floor of midbrain	Eye, 4 muscles of eyeball	Motor	Movements of eyeball, iris, lens, eyelid
IV.	**Trochlear**	Floor of midbrain	Eye, superior oblique muscles of eyeball	Motor	Rotation of eyeball
V.	**Trigeminal**	Side of medulla	Head, face, jaws, teeth	*Sensory* Motor	Forehead, scalp, upper eyelid, side of nose, teeth Movement of tongue, jaw muscles for chewing
VI.	**Abducens**	Side of medulla	External rectus muscle of eyeball	Motor	Rotation of eyeball
VII.	**Facial**	Side and floor of medulla	Anterior 2/3 tongue. Muscles of face, neck and chewing	*Sensory* Motor	Taste Facial expression, chewing, movement of neck
VIII.	**Auditory (acoustic)**	Side of medulla	Organ of Corti in cochlea Semicircular canals	*Sensory*	Hearing Equilibrium
IX.	**Glossopharyngeal**	Side of medulla	Posterior 1/3 tongue, mucous membrane and muscles of pharynx	*Sensory* Motor	Taste & touch Movements (swallowing) of pharynx
X.	**Vagus (pneumogastric)**	Side and floor of medulla	Muscles of pharynx, vocal cords, lungs, heart, oesophagus, stomach, intestine	*Sensory* Motor	Vocal cords, lungs Respiratory reflexes, peristaltic movements, speech, swallowing, secretion of gastric glands, inhibition of heart beat
XI.	**Spinal accessary**	Floor of medulla	Muscles of palate, larynx, vocal cords, neck, shoulder	Motor	Muscles of pharynx, larynx, neck, shoulder movements
XII.	**Hypoglossal**	Floor of medulla	Muscles of tongue, neck	Motor	Movements of tongue

and ganglia innervate the involuntary or smooth muscles of viscera, heart and glands and control the internal body environment.

Readers may refer to the note on autonomic nervous system described in the end of nervous system of rabbit in Chapter 30.

IMPORTANT QUESTIONS

» *Long Answer Type Questions*

1. Give a comparative account of brain of vertebrates.
2. Describe the brain of a lizard and compare it with that of a mammal.
3. Compare the brains of frog and rabbit.

» *Short Answer Type Questions*

1. Give in tabular form the origin, distribution, nature and function of cranial nerves in vertebrates.
2. How does a nerve impulse travel along a nerve cell across a synapse.
3. Write short notes on — (i) Acetylcholine, (ii) Autonomic nervous system, (iii) Conduction of nerve impulse, (iv) Neuron, (v) Synapses.

» *Multiple Choice Questions*

1. The branch of medical science dealing with the structure, functions and diseases of nervous system :
   (a) Neurology (b) Nephrology
   (c) Endocrinology (d) Cardiology
2. Connecting link between the receptors, central nervous system and effectors :
   (a) Central nervous system
   (b) Peripheral nervous system
   (c) Sympathetic nervous system
   (d) Parasympathetic nervous system
3. Connective tissue of nervous system :
   (a) Areolar (b) Adipose (c) Cartilage (d) Neuroglia
4. Nissel's granules are made up of :
   (a) DNA (b) RNA
   (c) Nucleoprotein (d) Thymine
5. A mass of cell bodies within the gray matter of brain or spinal cord :
   (a) Cyton (b) Neuroglia
   (c) Ganglion (d) Nucleus
6. Bipolar neurons are found in :
   (a) Cornea (b) Conjuctiva
   (c) Retina (d) Lens
7. The central nervous system in vertebrates is derived from :
   (a) Basal plate (b) Archenteron
   (c) Neural plate (d) Blastopore
8. Function of restiform bodies in elasmobranchs :
   (a) Maintenance of equilibrium
   (b) Swimming
   (c) Sound production
   (d) Steering
9. Cerebral hemispheres in Eutherians are connected internally by :
   (a) Corpus callosum (b) Corpus luteum
   (c) Corpus albicans (d) Cerebral aqueduct
10. Terminal nerves are numbered :
    (a) 11 (b) 12 (c) 13 (d) 0

ANSWERS

1. (a) 2. (b) 3. (d) 4. (b) 5. (d) 6. (c) 7. (c) 8. (a) 9. (a) 10 (d).

58

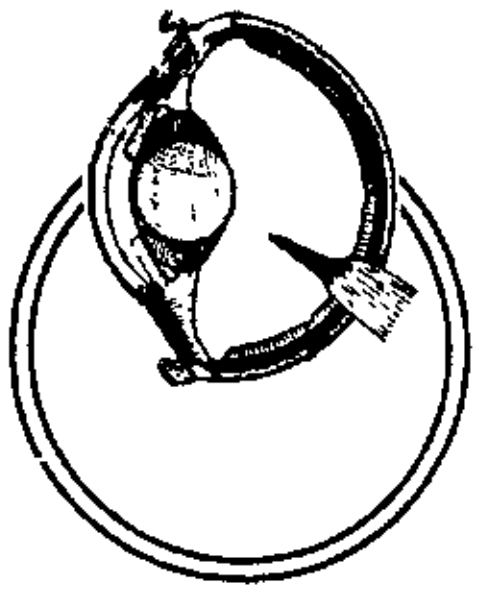

Receptor Organs in Vertebrates

Organisms are subjected to many influences from their surroundings constituting the environment. All changes in the environment, both external and internal, are known as *stimuli.* Organs of the body that detect these changes or stimuli are called *receptors* or *sense organs.* They receive information from the environment in the form of energy (mechanical, chemical, electrical, thermal or radiant) and change it into nerve impulses which are transmitted to the brain or spinal cord via afferent or sensory nerve fibres to which they are connected. Thus, sense organs have dual functions : (i) they *detect* environmental changes or stimuli and then (ii) *transmit* this information in the form of nerve impulses to the central nervous system. In turn, the central nervous system integrates the incoming information and sends out messages via efferent or motor nerve fibres to effector organs which respond in appropriate manner.

Common Senses

At least the following 5 senses are more common although more senses are recognized by the biologists.

(1) **Touch.** Includes contact, pressure, heat, cold, etc.
(2) **Taste.** For certain substances in solution.
(3) **Smell.** For votatile chemicals and gases in air.
(4) **Hearing.** For vibrations in air, water or solid.
(5) **Sight.** For light waves.

Classification of Sense Organs

Senses organs are classified in many ways.

1. General and special receptors. Various minute sense organs are distributed widely upon or within the body especially the skin. These *cutaneous* sense organs are collectively termed

Table 1. **Types of Receptors or Sense Organs According to Stimuli and Location.**

	Sense Organs or receptors	According to type of stimulus	According to location of stimulus	Stimuli	Functions
1.	**Skin** (cutaneous)	*Mechanoreceptors* *Thermoreceptors*	*Exteroceptors*	Contact temperature	Detecting touch, hot and cold, etc.
2.	**Muscles** (kinesthetic)	*Mechanoreceptors*	*Proprioceptor*	Mechanical stretch	Feeling and gauging pressures
3.	**Tongue** (gustatory)	*Chemoreceptor*	*Exteroceptors*	Dissolved chemicals	Tasting
4.	**Nose** (Olfactory)	*Chemoreceptor*	*Exteroceptor*	Volatile chemicals and gases in air	Smelling
5.	**Eyes** (visual)	*Photoreceptors*	*Exteroceptors*	Light	Seeing
6.	**Ears** (auditory)	*Statoacoustic*	*Exteroceptors*	Sound and gravity	Hearing and balancing

general receptors, for their exact functions are not clear and any one of them can not be related to a single sensation alone.

On the other hand, the tongue, nose, eyes and ears are termed *special receptors*. They are concentrated in small areas particularly on the cephalic end of the body. They respond to particular types of stimuli or special senses and their functions are better understood.

2. Types according to stimuli. Table 1 lists the main receptors or sense organs according to the type of stimuli they receive and their location in the body. In a broad sense, we can recognize the following types on the basis of the stimulus to which they are sensitive :

(a) Mechanoreceptors. These are stimulated by touch and pressure (skin), vibrations or sound and balance (ears).

(b) Chemoreceptors. These are sensitive to smell, that is chemical substances or odours in air (nose), and to taste, that is substances in solution (tongue).

(c) Photoreceptors. These are sensitive to light waves or sight (eyes).

(d) Thermoreceptors. Sensitive to heat and cold (skin).

(e) Nerve endings. Sensitive to pain (skin).

3. Types according to location. Receptors may also be classifies according to the location of stimulus.

(a) Exteroceptors. These receive environmental stimuli from outside the organism and supply information about the surface of the body (touch, pressure, taste, heat, etc.). These include eyes, ears, nose, taste buds and cutaneous sense organs. The exteroceptors inform the organism about food mate or enemy.

(b) Proprioceptors. These are stretch receptors present in the muscles, joints, tendons, connective and skeletal tissues. They supply information about the so-called kinesthetic sense of equilibrium and orientation. They act like pressure gauges and are responsible for maintenance of body posture.

(c) Interoceptors. These lie in various internal organs. They provide information about the internal body environment, such as CO_2 concentration, blood composition, pain, fullness, etc. They are responsible for maintaining an appropriate internal body environment necessary for the continued survival of the organism.

4. Somatic and visceral receptors. Exteroceptors and proprioceptors are also called *somatic receptors*. Similarly, interoceptors are also called *visceral receptors*.

Some sense organs have a dual role. For example, sensory epithelium of nose and taste buds serves both as exteroceptor (somatic) as well as visceral receptor.

The readers have already gone through description of various receptors or sense organs found in different vertebrate types such as dogfish *(Scoliodon)*, frog *(Rana)*, lizard *(Uromastix)*, pigeon *(Columba)* and rabbit *(Oryctolagus)*, treated in earlier chapters in this text. To describe them all here again will be merely a repetition of what has already been written elsewhere. Instead, the following description shall attempt to point out some of the more important differences among similar receptors in different classes of vertebrates.

Olfactory Organs in Vertebrates

Olfactory organs are special visceral chemoreceptors concerned with the sense of smell. These consist of a pair of cavities, the *olfactory* or *nasal sacs*, on the anterior end of head. Their external openings are called *nares* or *nostrils*. Cyclostomes have a single blind olfactory sac with a single external naris, but there are two olfactory nerves. In fishes, olfactory sacs are blind sacs except in all lobe-finned fishes and Dipnoi having internal nares. In all air-breathing animals or tetrapods, each olfactory sac has an external as well as an internal nostril. Unlike other receptors, processes of olfactory cells lead directly to brain so that they are termed *neuro-sensory cells*.

Olfactory sense is well developed in fishes and mammals. But birds are practically devoid of it except in the kiwi. It has been experimentally demonstrated that salmon fishes with plugged nasal sacs are unable to find their home river tributaries in which to spawn. It has been said that man can distinguish seven primary odours (camphoraceous, musky, floral, pepperminty, ethereal, pungent and putrid). In most vertebrates groups, olfaction provides vital information to search food, predators, mates, and even the way home.

Organs of Jacobson or vomeronasal organs are independent chambers below nasal cavities, found in most tetrapods, although they are sometimes vestigial.

Gustatory Organs in Vertebrates

Sense of taste or gustation is the perception of dissolved substances by small group of receptive cells called *taste buds* (Fig. 1). A taste bud is an ovoid cluster of columnar epithelial cells. Each of which bears a delicate *bristle* or *hair* at its free end. The ends of several sense cells round a small depression called *taste pore* through which the fluid from oral cavity gets access to sense cells. These cells in turn are connected to nerves. These occur in all vertebrates and are fairly uniform in structure. In *amphioxus* certain cellular entities are present on cirri, resembling with taste buds, but their function is still unknown. In lower vertebrates, such as fishes, taste buds occur in many parts of the mouth and pharynx, even on the skin of head. In catfish they are abundant on the whiskers. In bottom - feeders or scavengers, they are distributed over the entire body surface.

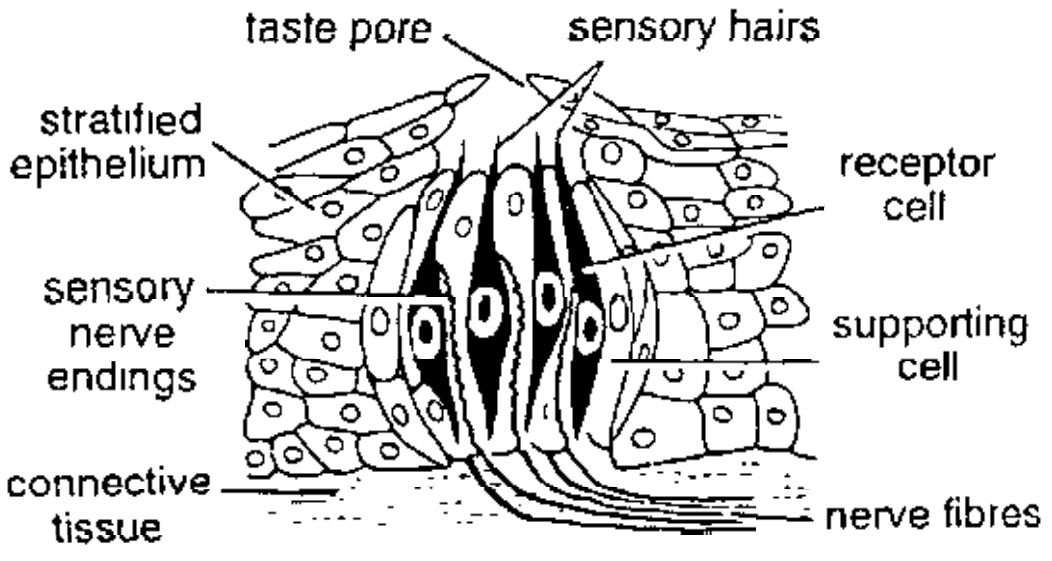

Fig. 1. Diagrammatic representation of a taste bud.

In tetrapods, the taste buds are restricted to the tongue, palate and pharynx. Taste buds are abundant on the papillae of tongue. They are most abundant in mammals but least abundant in birds. Taste buds are supplied by V, VII, IX and X cranial nerves. In man, taste buds on tongue can distinguish 4 types of fundamental tastes : sweet, sour, bitter and salty. The papillae on the mammalian tongue may be *vallate* or *foliate*. Number of taste buds on papillae also varies from animal to animal e.g., in sheep, it is 48, in cow it is 1760, in pig 4760. Thus, for example in cow which has 20 papillae, the number of taste bud is about 35000 in all. In some cases, the sensation of taste is in reality due to sense of smell. For example, many spices have relatively little taste, but affect the sense of smell powerfully. During bad cold, when access to the olfactory organs in the nose becomes difficult, the food appears tasteless.

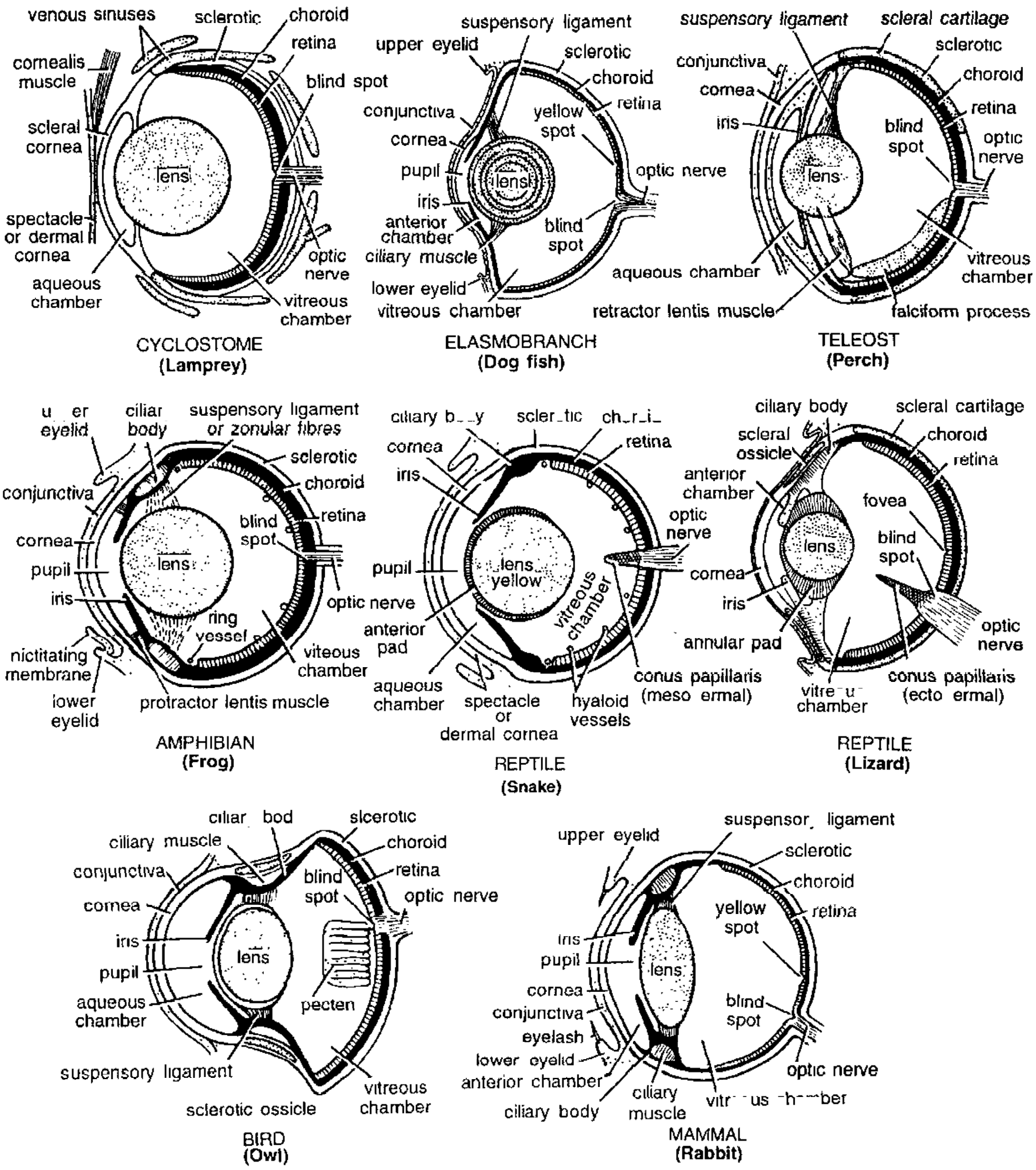

CYCLOSTOME **(Lamprey)**

ELASMOBRANCH **(Dog fish)**

TELEOST **(Perch)**

AMPHIBIAN **(Frog)**

REPTILE **(Snake)**

REPTILE **(Lizard)**

BIRD **(Owl)**

MAMMAL **(Rabbit)**

Fig. 2. Eyes of different vertebrates in sagital section.

Photoreceptors or Eyes

The sense of sight is due to stimulation of the eyes. Vertebrates have two types of eyes — (i) Unpaired *median* and (ii) Paired *lateral.*

1. Median eyes. Median eyes were abundant in most ancient fishes, amphibians and reptiles. They are also found in some living vertebrates in the form of *pineal* and *parapineal organs* formed as dorsal evaginations of the diencephalon of forebrain. They are light sensitive in lampreys (cyclostomes). They have a lens and sensory innervation but lack a retina and do not form an image. Pineal and parapineal bodies probably do not serve as light receptors above reptiles. The parapineal of reptiles, when present *(Sphenodon)*, is covered by a translucent tissue. It serves as a third eye and is often termed the *parietal eye*.

2. Lateral eyes. The lateral eyes of all vertebrates are essentially similar (Fig. 2). They are of the 'camera type' with a lens which focuses images of external objects on the sensitive retina serving as a photographic film. However, the eyes of lower vertebrates (fish and amphibians), which live in water, differ from the eyes of higher vertebrates (reptiles, birds and mammals), which live out of water, in several important respects. It is because the problems associated with sight under water are different from those in the air.

(a) Eyelids and tear glands. Water itself cleans and moistens the eye, so that fishes lack movable eyelids and tear glands.

(b) Refractive index and cornea. Refractive index of water is nearly the same as that of cornea. Thus, the cornea of a fish's eye does not bend light rays. Thus cornea remains flat in lower vertebrates but bulges out in higher vertebrates.

(c) Shape of lens. Most refraction is achieved through lens which is nearly spherical in shape with greater refractive power in fishes. On the other hand, tetrapods have a flat or oval lens with less refractive power.

(d) Method of accommodation. It also differs in lower and higher vertebrates. Fishes, amphibians and snakes focus by moving the lens back and forth in camera fashion. On the other hand, mammals, birds and reptiles other than snakes have tough sclera and immovable lens. However, their lens has elastic properties so that the shape of the lens is changed so as to alter its magnifying power.

Amphioxus has no eye but numerous *photoreceptor cells* are found in the nerve cord. Cyclostomes have degenerate type of eye, in which eye ball is buried under the thick skin that too is without cornea, iris, lids and ciliary apparatus. *Geotria macrophthalmus*, a freshwater cyclostome of Africa has large eye. Eyes in Elasmobranchs are large, rounded cornea that helps the spherical lens in focusing. The lens can project through the pupil and see to some extent, things on the sides. In a few elasmobranchs at the center of the choroids there is an additional layer (*Tapetum lucidum*), made of reflecting crystals. In the outer part of choroids of a few teleosts, a silvery or greenish golden layer is found called, *argentia*, which acts as reflector. Fishes are mostly colorblind and do not have cones in the retina. Among amphibians, eyes are normally small in aquatic urodeles and sunken into skin. Amphibian eye is simpler than fishes. It lacks tapetum lucidum and argentia. Besides this, retina also does not have fovea. Reptilian eyes are lateral in position and their field of vision is also different. Reptilian eyes are with well developed eyelids and glands. The lens is less convex than amphibians. Avian eyes are relatively large, occupying much space in the head. Eye ball is not spherical and has good power of accommodation. It the lumen of eye, a fan like organ *pectin* is found, which is probably nutritive in function. Features of mammalian eye have already been discussed.

Statoacoustic Organs or Ears

In cyclostomes the ear is said to be most primitive and has a single canal flattened on the bottom and rounded dorsally. It bears ampullae at both the ends. The lamprey (*Petromyzon*) and other cyclostomes have paired canals which are dorso-ventral in position. The tube is lined by epithelial cells equipped with sensory processes

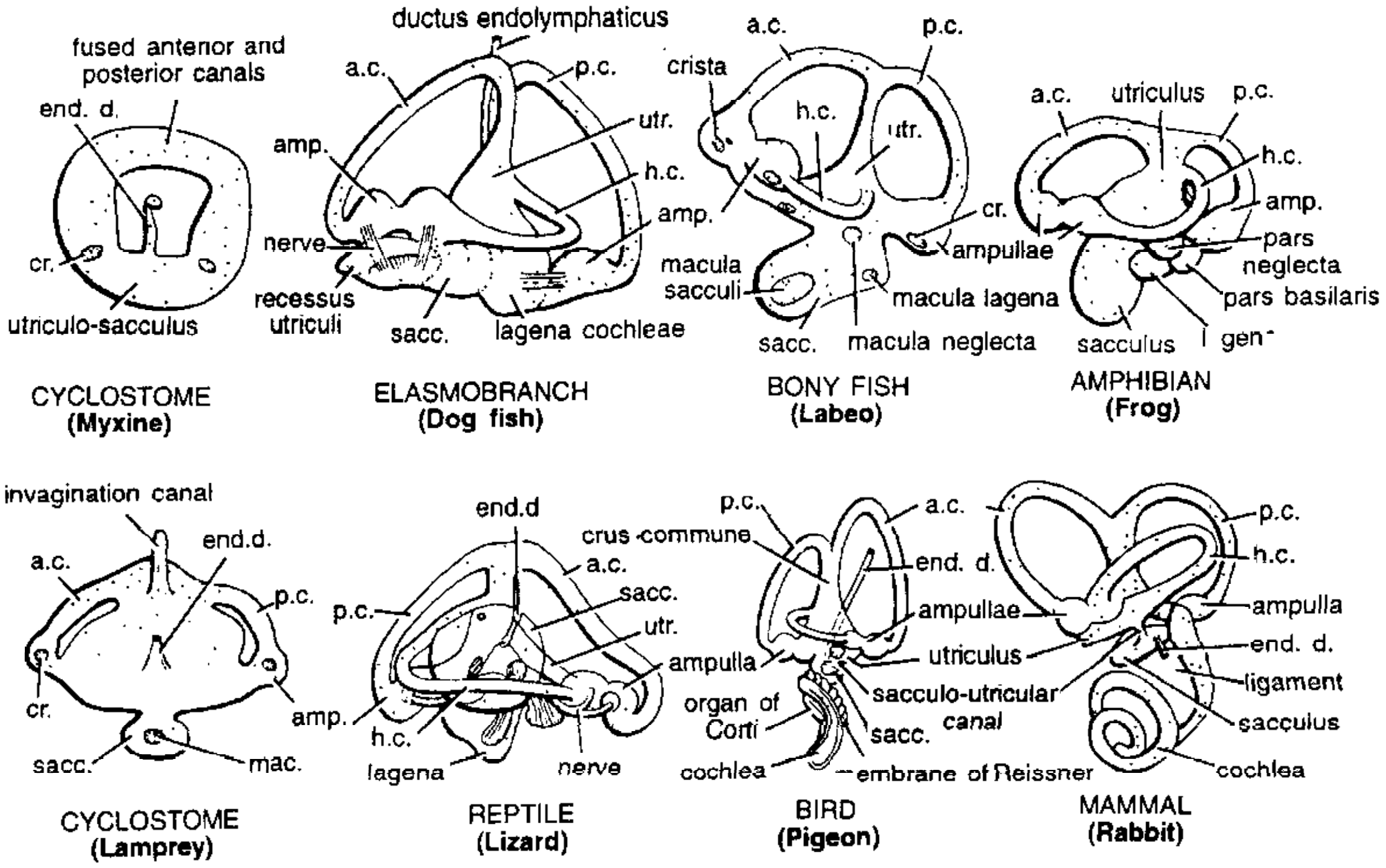

CYCLOSTOME **(Myxine)**

ELASMOBRANCH **(Dog fish)**

BONY FISH **(Labeo)**

AMPHIBIAN **(Frog)**

CYCLOSTOME **(Lamprey)**

REPTILE **(Lizard)**

BIRD **(Pigeon)**

MAMMAL **(Rabbit)**

Fig. 3. Internal ears of representiative vertebrates a.c—anterior vertical semicircular canal. amp.—ampulla. cr.—crista. end.d.—endolymphatic duct. h.c.—horizontal canal. mac.—macula. p.c.—posterior vertical canal. sacc.—sacculus. utr.—utriculus.

and indicates the body position. This condition of cyclostomes is degenerate than primitive. It is so because of its semi attached host.

In fishes. The two senses of hearing and equilibrium are associated with the ears (Fig. 3). All the vertebrates possess a pair of inner ears or *membranous labyrinths*, embedded within the otic capsules of the skull lateral to the hindbrain. Each membranous labyrinth consists of 3 *semicircular canals* (only 1 or 2 in cyclostomes), a *utriculus* and a *sacculus*. Sacculus in fishes forms a rudimentary diverticulum, the *lagena*, which is a forerunner of cochlea of higher vertebrates, concerned with audition. Teleost fishes of the order Cypriniformes (catfishes, suckers, carps, etc.) utilize an air-filled swim bladder as a hydrophone. Sound waves in water, create waves of similar frequency in the gas filled bladder. These are transmitted via a chain of small bones, the *weberian ossicles*, to the sacculus. Weberian ossicles are modified transverse processes of the first 4 (occasionally 5) trunk vertebrae.

In tetrapods. In tetrapods, a middle ear cavity is added containing an ear ossicle, the *columella auris* or *stapes*, for transmitting sound vibrations from external tympanic membrane to a fenestra ovalis in the otic capsule (Fig. 3). An outer ear canal or external auditory meatus is also developed in amniotes. The lagena of fishes becomes a papilla called *cochlea* in amphibians. It gradually elongates in higher vertebrates into a *cochlear duct* containing the actual receptive structure, the *organ of Corti*.

The hearing apparatus of mammals is basically similar but much more elaborate. The cochlear duct is spirally coiled. In most mammals, an external flap, called *auricle* or *pinna*, collects and directs sound waves into the external auditory meatus. Instead of a single columella, the middle ear cavity in mammals is crossed by three *ear ossicles* : malleus, incus and stapes.

IMPORTANT QUESTIONS

» *Long Answer Type Questions*

1. What are receptors? How would you classify them?
2. Describe the structure of eye and explain the process of focusing in vertebrates.
3. Describe the structure of ear invertebrates.
4. Explain the mechanism of hearing and equilibrium in vertebrates.

» *Short Answer Type Questions*

1. Write short notes on — (i) Accommodation of eye, (ii) Chemoreceptors, (iii) Cochlear duct, (iv) Eustachian tube, (v) Mechanoreceptors, (vi) Nerve endings, (vii) Organ of Jacobson, (viii) Parietal eye, (ix) Proprioceptors, (x) Taste buds.

» *Multiple Choice Questions*

1. Receptors stimulated by touch and pressure, vibrations and balance :
   (a) Chemoreceptors (b) Mechanoreceptors
   (c) Photoreceptors (d) Thermoreceptors
2. Which of the following is a visceral receptor?
   (a) Interoceptor (b) Propioceptor
   (c) Exteroceptor (d) Thermoreceptor
3. Muscles are :
   (a) Thermoreceptors (b) Mechanoreceptors
   (c) Chemoreceptors (d) Photoreceptors
4. In tetrapods taste buds are present on :
   (a) Tongue (b) Palate
   (c) Pharynx (d) All
5. Organ of Pecten is found in the eye of :
   (a) Fish (b) Frog (c) Snake (d) Bird

ANSWERS

1. (b) 2. (a) 3. (b) 4. (d) 5. (d).